



**BJOG**

An International Journal of  
Obstetrics and Gynaecology



Royal College of  
Obstetricians &  
Gynaecologists

# Management of Monochorionic Twin Pregnancy

Green-top Guideline No. 51

November 2016

*Please cite this paper as:* Kilby MD, Bricker L on behalf of the Royal College of Obstetricians and Gynaecologists. Management of monochorionic twin pregnancy. BJOG 2016; 124:e1–e45.



## Management of Monochorionic Twin Pregnancy

This is the second edition of this guideline, previously published under the same title in December 2008.

### Executive summary of recommendations

#### *Diagnosis of monochorionic twin pregnancy*

How is monochorionicity diagnosed prenatally and what is the accuracy of prenatal ultrasound chorionicity allocation?

**All women with a twin pregnancy should be offered an ultrasound examination between 11<sup>+0</sup> weeks and 13<sup>+6</sup> weeks of gestation (crown–rump length 45–84 mm) to assess fetal viability, gestational age and chorionicity, and to exclude major congenital malformations.**

**B**

**Chorionicity should be determined at the time the twin pregnancy is detected by ultrasound based upon the number of placental masses, the appearance of the membrane attachment to the placenta and the membrane thickness. This scan is best performed before 14 weeks of gestation. [New 2016]**

**D**

**A photographic (thermal copy) record should be taken and placed in the patient's notes documenting the ultrasound appearance of the membrane attachment to the placenta and an electronic copy stored (Appendix II).**

✓

**If there is uncertainty about the diagnosis of chorionicity, a photographic record of the ultrasound appearance of the membrane attachment to the placenta should be retained and a second opinion should be sought.**

✓

**If there is still doubt in the diagnosis of chorionicity, the woman should be referred to a specialist without delay, as chorionicity is best determined before 14 weeks of gestation.**

**D**

**On ultrasound, the fetuses in twin pregnancies should be assigned nomenclature (i.e. upper and lower, or left and right) and this should be clearly documented in the woman's case notes to ensure consistency throughout pregnancy. [New 2016]**

**C**

### *Outcome of monochorionic twin pregnancy*

What is the outcome of monochorionic compared with dichorionic twin pregnancies?

**Clinicians and women should be aware that monochorionic twin pregnancies have higher fetal loss rates than dichorionic twin pregnancies, mainly due to second trimester loss and, overall, may have a higher risk of associated neurodevelopmental morbidity. This should form part of the parental counselling.**



### *Optimal screening for chromosomal abnormalities, structural abnormalities and other fetal complications in monochorionic twin pregnancies*

What is the optimum method of screening for chromosomal abnormalities in monochorionic twin pregnancies?

**Women with monochorionic twins who wish to have aneuploidy screening should be offered nuchal translucency measurements in conjunction with first trimester serum markers (combined screening test) at 11<sup>+0</sup> weeks to 13<sup>+6</sup> weeks of gestation (crown–rump length 45–84 mm). [New 2016]**



**In women with monochorionic twin pregnancies who 'miss' or who have unsuccessful first trimester screening for aneuploidy, second trimester screening by the quadruple test should be offered. [New 2016]**



**Early data with noninvasive prenatal testing are encouraging, but results should be interpreted with caution until larger studies have been carried out. [New 2016]**



What is the optimum method of screening for structural abnormalities in monochorionic twin pregnancies?

**All monochorionic twins should undergo a routine detailed ultrasound scan between 18 and 20<sup>+6</sup> weeks of gestation which includes extended views of the fetal heart anatomy (as recommended in the Fetal Anomaly Screening Programme screening of a singleton fetus).**



What is the optimum ultrasound regimen for monochorionic twin pregnancies?

**Fetal ultrasound assessment should take place every 2 weeks in uncomplicated monochorionic pregnancies from 16<sup>+0</sup> weeks onwards until delivery (Appendix III).**



**At every ultrasound examination, liquor volume in each of the amniotic sacs should be assessed and a deepest vertical pocket (DVP) depth measured and recorded, as well as the umbilical artery pulsatility index (UAPI). Fetal bladders should also be visualised. Although first presentation of twin-to-twin transfusion syndrome (TTTS) is rare after 26<sup>+0</sup> weeks of gestation, it can occur and therefore, scans should be performed at 2-weekly intervals in uncomplicated monochorionic twins until delivery (Appendix III). [New 2016]**



**From 16<sup>+0</sup> weeks of gestation, fetal biometry should be used to calculate an estimated fetal weight (EFW) and the difference in EFW calculated and documented. As the risk of selective growth restriction (sGR) extends to delivery, this should be performed at 2-weekly intervals until delivery. [New 2016]**



What are the optimum methods of screening for specific complications of monochorionic twin pregnancies?

Screening for TTTS

**Screening for TTTS by first trimester nuchal translucency measurements should not be offered. [New 2016]**



**Women with monochorionic twin pregnancies should be asked to report sudden increases in abdominal size or breathlessness to healthcare professionals in their secondary or tertiary centres as this may be a manifestation of TTTS.**



**Screening for TTTS should be by ultrasound examination from 16<sup>+0</sup> weeks onwards, at 2-weekly intervals, noting and recording fetal biometry and liquor volumes (DVP). Fetal bladders should also be visualised.**



Screening for twin anaemia-polycythaemia sequence (TAPS)

**TAPS should be screened for following fetoscopic laser ablation for TTTS and in other complicated monochorionic pregnancies requiring referral to a fetal medicine centre (such as those complicated by sGR) by serial middle cerebral artery peak systolic velocity (MCA PSV). [New 2016]**



Screening for sGR

**At each scan from 20 weeks of gestation (at 2-weekly intervals) onwards, calculate EFW discordance using two or more biometric parameters. Calculate percentage EFW discordance using the following formula:  $([\text{larger twin EFW} - \text{smaller twin EFW}] / \text{larger twin EFW}) \times 100$ . Liquor volumes as DVP should be measured and recorded (to differentiate from TTTS). [New 2016]**



**An EFW discordance of more than 20% is associated with an increase in perinatal risk. Such pregnancies should be referred for assessment and management in fetal medicine units with recognised relevant expertise. [New 2016]**



**Umbilical artery Doppler evaluation in monochorionic twins with sGR allows definition of prognosis and potential morbidity. In particular, those with absent or reversed end-diastolic velocities (AREDV) and 'cyclical' umbilical artery Doppler waveforms (intermittent AREDV) are at increased risk of perinatal mortality and morbidity (Appendix IV). [New 2016]**



*Management of complex pathologies associated with a monochorionic twin pregnancy*

The management of TTTS

How useful are grading systems for severity of TTTS in establishing prognosis?

**At diagnosis, TTTS should be staged using the Quintero system. In addition, measurement of umbilical artery Doppler velocities, MCA PSV and ductus venosus Doppler studies should be performed and documented.**



What is (are) the optimal treatment(s) of TTTS and their outcomes?

**TTTS should be managed in conjunction with fetal medicine centres with recourse to specialist expertise and treatment in supraregional centres.**



**TTTS presenting before 26 weeks of gestation should be treated by fetoscopic laser ablation rather than amnioreduction or septostomy. There is evidence that the fetoscopic laser ablative method should be the Solomon technique.**



**Centres performing fetoscopic laser ablation should perform at least 15 procedures per year (rolling 3-year average). [New 2016]**



**Weekly ultrasound assessment (including examination of the fetal brain, heart and limbs) and serial measurements of UAPI, MCA PSV and ductus venosus Doppler velocities should be performed. After 2 weeks post treatment, the ultrasound interval can be increased to every 2 weeks (noting UAPI, MCA PSV and DVP) with documentation of adequate fetal growth (by calculating EFW).**



**In treated TTTS pregnancies, ultrasound examination of the fetal heart should be performed by the fetal medicine specialist to exclude functional heart anomalies.**



When should the delivery of monochorionic twin pregnancies complicated by TTTS take place?

**Delivery of monochorionic twin pregnancies previously complicated by TTTS and treated should be between 34<sup>+0</sup> and 36<sup>+6</sup> weeks of gestation. [New 2016]**



The management of sGR

**sGR in monochorionic twins requires evaluation in a fetal medicine centre with expertise in the management of such pregnancies. [New 2016]**



**In cases of early-onset sGR in association with poor fetal growth velocity and abnormal umbilical artery Doppler assessments, selective reduction may be considered an option. [New 2016]**



**In sGR, surveillance of fetal growth should be undertaken at least every 2 weeks with fetal Doppler assessment (by umbilical artery and middle cerebral artery pulsatility index, and peak systolic velocity). If umbilical artery Doppler velocities are abnormal, the Doppler assessments should be undertaken in line with national guidance, measuring ductus venosus waveforms. [New 2016]**



**Clinicians should be aware that there is a longer 'latency period' between diagnosis and delivery in monochorionic twins complicated by sGR compared with growth restriction in dichorionic twin pregnancy or singleton pregnancy. [New 2016]**



**Abnormal ductus venosus Doppler waveforms (reversed flow during atrial contraction) or computerised cardiocography short-term variation should trigger consideration of delivery. [New 2016]**



In type I sGR, planned delivery should be considered by 34–36 weeks of gestation if there is satisfactory fetal growth velocity and normal umbilical artery Doppler waveforms. [New 2016]



In type II and III sGR, delivery should be planned by 32 weeks of gestation, unless fetal growth velocity is significantly abnormal or there is worsening of the fetal Doppler assessment. [New 2016]



It is important to prospectively inform parents that in sGR and TTTS (even after apparently successful treatment) there can be acute transfusional events (which are neither predictable nor preventable) and therefore, despite regular monitoring, there may still be adverse perinatal outcomes. [New 2016]



Management of TAPS

Clinicians should be aware that the natural history, fetal and neonatal implications, and optimal treatment and/or surveillance of monochorionic pregnancies diagnosed with TAPS are poorly established. [New 2016]



The management of monochorionic twin pregnancies complicated by single twin demise

What are the consequences for the surviving twin after fetal death of the co-twin in a monochorionic pregnancy and what is optimal clinical management?

Clinicians should be aware that monochorionic pregnancies not complicated by TTTS, sGR or TAPS are still at risk of fetal death and neurological abnormality.



After a single fetal death in a monochorionic pregnancy, clinicians should be aware that the risks to the surviving twin of death or neurological abnormality are of the order of 15% and 26%, respectively. [New 2016]



Single fetal death in a monochorionic pregnancy should be referred and assessed in a fetal medicine centre, with multidisciplinary expertise to manage these cases.



Fetal magnetic resonance imaging of the brain may be performed 4 weeks after co-twin demise to detect neurological morbidity if this information would be of value in planning management.



How should fetal anaemia be monitored after single twin intrauterine death?

Fetal anaemia may be assessed by measurement of the fetal MCA PSV using Doppler ultrasonography.



### *Timing and mode of delivery in uncomplicated monochorionic pregnancies*

What is the optimal timing and method of delivery for otherwise uncomplicated monochorionic pregnancies (without TTTS, sGR or TAPS)?

**Women with monochorionic twins should have timing of birth discussed and be offered elective delivery from 36<sup>+0</sup> weeks with the administration of antenatal steroids, unless there is an indication to deliver earlier. [New 2016]**

C

**It is appropriate to aim for vaginal birth of monochorionic diamniotic twins unless there are other specific clinical indications for caesarean section.**

A

### *Monochorionic monoamniotic (MCMA) pregnancies*

What are the specific problems of MCMA pregnancies and how should they be managed?

**MCMA twins almost always have umbilical cord entanglement when visualised using colour flow Doppler. Such a finding has not consistently been demonstrated to contribute to overall morbidity and mortality. [New 2016]**

D

**MCMA twins have a high risk of fetal death and should be delivered by caesarean section between 32<sup>+0</sup> and 34<sup>+0</sup> weeks. [New 2016]**

D

### *Higher order multiple pregnancies with reference to monochorionicity*

What is the outcome of monochorionic and dichorionic compared with trichorionic triplet pregnancies?

**Clinicians should be aware that monochorionic/dichorionic triplet pregnancies have higher fetal loss rates than trichorionic triplet pregnancies and may be complicated by feto–fetal transfusion syndrome, sGR and TAPS.**

C

**Selective reduction should be discussed in all higher order pregnancies including triplets. [New 2016]**

✓

**Increased ultrasound surveillance is warranted in a fetal medicine centre with expertise to manage such cases.**

✓

### *Discordant abnormalities in monochorionic pregnancies*

What is the incidence of and the therapeutic options for discordant abnormalities in monochorionic pregnancies, including twin reversed arterial perfusion sequence?


**Monochorionic twins that are discordant for fetal anomaly must be referred promptly for assessment and counselling in a fetal medicine centre with consideration for treatment.**


✓

**Karyotyping of monochorionic twins should be managed in a fetal medicine centre. [New 2016]**


✓


Meticulous mapping of the position of the twins within the uterus should be performed both at the time of prenatal diagnostic tests and invasive treatments. [New 2016] 

During amniocentesis, both amniotic sacs should be sampled in monochorionic twin pregnancies, unless monochorionicity is confirmed before 14 weeks and the fetuses appear concordant for growth and anatomy. [New 2016] 

Prior to invasive testing or in the context of twins discordant for an abnormality, selective reduction should be discussed and made available to those requesting the procedure after appropriate counselling. [New 2016] 


Monitoring for disseminated intravascular coagulopathy is not indicated in monochorionic twin pregnancies undergoing selective reduction. [New 2016] 

Selective feticide by intravascular injection of an abortifacient is not an option in monochorionic pregnancies because of the presence of placental anastomoses. The potential risks of intrafetal/umbilical cord ablative procedures should be discussed prospectively, including the risk of co-twin loss and neurological morbidity. [New 2016] 


Documentation and discussion of heterokaryotypic monozygotic karyotypic abnormalities should take place. [New 2016] 


### *Conjoined twins*


How are conjoined twins diagnosed and what are the outcomes?

Conjoined twins are exceedingly rare and prenatal assessment is required in a tertiary fetal medicine centre so that diagnosis can be confirmed and prognosis discussed in conjunction with a multidisciplinary team. [New 2016] 

*What are the training competencies required for managing monochorionic pregnancies?*

All sonographers who undertake routine ultrasound scans during pregnancy must be trained to establish chorionicity and the correct labelling of twins. 

All sonographers who undertake midtrimester (18<sup>+0</sup>–20<sup>+6</sup> weeks) and fetal growth scans of monochorionic twins should be made aware of the appearances of TTTS, sGR and TAPS, and the need to refer patients on to specialist centres if such features present. 

Fetal medicine centres undertaking fetal therapy for relatively rare complications of monochorionic twins should have a minimum of two experienced operators and more than 15 cases per year (rolling 3-year average) to maximise perinatal outcomes and minimise long-term morbidity. 



## 1. Purpose and scope

The purpose of this guideline is to evaluate and provide recommendations on best practice for the management of problems associated with monochorionic placentation and their effects upon multiple pregnancies. The use of ultrasound to determine chorionicity and amnionicity is key to the management of multiple pregnancies and the potential risks to the fetuses. This guideline will outline the best evidence to guide clinical care, including fetal surveillance and treatment of complications for monochorionic multiple pregnancy. It is important to emphasise that this guideline is focused upon the management of monochorionic multiple pregnancies rather than all multiple pregnancies.

It is also recognised that women carrying a monochorionic pregnancy (most commonly twins) may have concerns and anxieties surrounding their pregnancy. This requires accurate information given in a sensitive manner by healthcare professionals and support by a multidisciplinary team, ideally within a multiple pregnancy clinic.<sup>1</sup> Support is also often given in conjunction with the Twins And Multiple Births Association and The Multiple Births Foundation within the UK.

## 2. Introduction and background epidemiology

A monochorionic pregnancy is a multiple pregnancy, most commonly a twin pregnancy, in which babies are dependent on a single, shared placenta. Approximately 30% of twin pregnancies in the UK are monochorionic. Monochorionic placentation can also occur in rarer, higher order multiples, especially triplets (i.e. dichorionic or monochorionic triplets).

There has been an increase in all types of multiple pregnancies with the increasing use of assisted reproductive technology, sociodemographic changes in our population associated with migration and deferment of pregnancy to a later maternal age. Assisted reproductive technology increases the prevalence of both dichorionic and monochorionic twinning. However, using day 5 blastocyst transfers seems to have a significantly higher rate of monozygotic twinning (adjusted OR 2.04, 95% CI 1.29–4.48) compared with cleavage stage day 3 transfers.<sup>2,3</sup>

Monochorionic and dichorionic twin pregnancies have increased risks of preterm birth, fetal growth restriction (FGR), pre-eclampsia, postpartum haemorrhage and postnatal complications, such as infant feeding difficulties and adverse puerperal mood change.<sup>1,4</sup>

The particular challenges of monochorionic pregnancies arise from the shared placenta and vascular placental anastomoses that are almost universal and connect the fetal circulations of both twins.

Specific complications associated with inter-twin vascular anastomoses are listed in Table I. Note that there may occasionally be some challenging diagnostic overlap among these definitions (e.g. twin-to-twin transfusion syndrome [TTTS] versus selective growth restriction [sGR] with reduced liquor around the smaller twin – see section 6.4.3):

- TTTS
- sGR
- twin anaemia-polycythaemia sequence (TAPS)
- twin reversed arterial perfusion (TRAP) sequence
- single intrauterine death; although not exclusive to monochorionic twin pregnancy, it is more common and has global effects on the co-twin.

---

In addition, the consequences for single fetal death and the management of discordant fetal anomalies (i.e. structural and chromosomal anomalies) in monochorionic twins is important.

Monochorionic diamniotic (MCDA) twin pregnancies carry a higher risk of overall fetal and perinatal loss compared with dichorionic pregnancies. Furthermore, monochorionic monoamniotic (MCMA) pregnancies, where both twins are in a single amniotic sac (1% of monochorionic twins), carry a very high risk of perinatal loss, most commonly before 24 weeks.<sup>1,4–7</sup>

Almost all monochorionic placentas contain vascular anastomoses running between the two fetal umbilical cords within and on the surface of the placenta. These connect the fetal circulations. In 80% of cases, these are bidirectional vascular anastomoses which rarely lead to haemodynamic imbalance between the fetal circulations, but allow a direct vascular connection between the twins with an increased risk of fetal death.<sup>8,9</sup>

In TTTS, which complicates up to 15% of monochorionic pregnancies,<sup>4</sup> the placentas have a predominance of unidirectional artery–vein anastomoses. This may lead to a haemodynamic imbalance within the circulations of the twins, directly adversely affecting fetal cardiac function, fetoplacental perfusion, but also adversely affecting fetal renal function by discordant activation of the renin–angiotensin axis.<sup>4,10</sup>

Postnatal perfusion studies have noted unequal placental ‘territory’ shared by the fetuses with associated marginal or ‘velamentous’ cord insertions. Such findings are common both in TTTS and sGR (which is often associated with TTTS).<sup>9,11–13</sup>

Very rarely, TTTS complicates MCMA twin pregnancies, as well as both dichorionic and monochorionic triplet pregnancies.<sup>11,14</sup>

TAPS is an important association in complicated monochorionic pregnancies, especially TTTS, occurring in up to 13% of cases post laser ablation.<sup>15</sup> It may relatively rarely be associated with apparently uncomplicated MCDA twins. The pathogenesis of TAPS is evidenced by postnatal placental injection studies demonstrating ‘miniscule’ artery–vein anastomoses (less than 1 mm) allowing the slow transfusion of blood from the donor to the recipient. This may be associated with highly discordant haemoglobin levels at birth (80 g/l or greater).<sup>15–18</sup>

Significant intrauterine fetal size discordance (difference in estimated fetal weight [EFW] of greater than 20%), termed ‘selective growth restriction’ (sGR), occurs in up to 15% of monochorionic twins in the absence of TTTS and in over 50% of monochorionic twins complicated by TTTS.<sup>19</sup> sGR is recognised as a specific monochorionic twin pathological entity associated with a significant differing placental territory between each fetus, inter-fetal placental anastomoses and abnormal fetoplacental blood flow.<sup>13</sup> The incidence of size discordance is as great in dichorionic pregnancies in some series,<sup>20</sup> but management of discordant growth is more complex in monochorionic pregnancies due to the associated placental anastomoses conjoining the fetal circulations.

It is recognised that in monochorionic twin pregnancies, because of these potential and specific complications, there may be significant anxiety and concern in parents, even if such abnormalities are not present. Accurate information presented in a sensitive manner during discussions is important so as to allay unnecessary fears, while imparting to couples the importance of appropriate increased prenatal surveillance.<sup>1,5,6</sup>

**Table 1.** Complications associated with inter-twin vascular anastomoses

<p><b>TTTS (Quintero staging)</b> Associated with 15% of monochorionic twins</p>	<ul style="list-style-type: none"> <li>I <b>A significant discordance in amniotic fluid volumes.</b> This is defined as oligohydramnios with deepest vertical pocket (DVP) &lt; 2 cm in donor sac and polyhydramnios in the recipient sac (DVP &gt; 8 cm before 20 weeks of gestation and &gt; 10 cm after 20 weeks of gestation). Donor bladder visible and Doppler normal.</li> <li>II Bladder of the donor twin not visible and severe oligohydramnios due to anuria. Doppler studies are not critically abnormal.</li> <li>III Doppler studies are critically abnormal in either the donor or recipient, with typically abnormal umbilical arterial Doppler velocities in the donor and/or abnormal venous Doppler velocities in the recipient (reversed flow during atrial contraction within the ductus venosus and/or pulsatile umbilical vein velocities).</li> <li>IV Ascites, pericardial or pleural effusion, scalp oedema or overt hydrops present usually in the recipient.</li> <li>V One or both babies have died (not amenable to therapy).</li> </ul>
<p><b>TAPS</b> 2% of uncomplicated monochorionic diamniotic (MCDA) and up to 13% of monochorionic twins post laser ablation</p>	<p>Signs of fetal anaemia in the donor and polycythaemia in the recipient <b>without</b> significant oligohydramnios/polyhydramnios being present. Donor has increased middle cerebral artery peak systolic velocity (MCA PSV) (&gt; 1.5 multiples of the normal median) and recipient has decreased MCA PSV (&lt; 1.0 multiples of the normal median).</p>
<p><b>sGR</b> (growth discordance of &gt; 20%) Approximately 10–15% of monochorionic twins</p>	<ul style="list-style-type: none"> <li>I Growth discordance but positive diastolic velocities in both fetal umbilical arteries.</li> <li>II Growth discordance with absent or reversed end-diastolic velocities (AREDV) in one or both fetuses.</li> <li>III Growth discordance with cyclical umbilical artery diastolic waveforms (positive followed by absent then reversed end-diastolic flow in a cyclical pattern over several minutes [intermittent AREDV; iAREDV]).</li> </ul>
<p><b>TRAP sequence</b> Approximately 1% of monochorionic twins</p>	<p>Acardiac twin (with usually no cardiac tissue) being perfused by the anatomically 'normal' pump twin through a large artery–artery anastomosis on the placental surface.</p>

### 3. Identification and assessment of evidence

This guideline was developed in accordance with standard methodology for producing Royal College of Obstetricians and Gynaecologists (RCOG) Green-top Guidelines. The Cochrane Library (including the Cochrane Database of Systematic Reviews and the Database of Abstracts of Reviews of Effects [DARE]), EMBASE, Trip, MEDLINE and PubMed (electronic databases) were searched for relevant randomised controlled trials, systematic reviews and meta-analyses. The search was restricted to articles published between 1966 and 2015. The databases were searched using the relevant Medical Subject Headings (MeSH) terms, including all subheadings, and this was combined with a keyword search. Search words included 'monochorionic twin', 'TTTS', 'twin twin transfusion syndrome', 'TRAP syndrome', 'amnioreduction', 'laser ablation', 'septostomy' and 'cord occlusion' and the search was limited to humans and the English language. The National Library for Health and the National Guideline Clearinghouse were also searched for relevant guidelines and reviews. The

most important of these is the 2011 National Institute for Health and Care Excellence (NICE) clinical guideline 129,<sup>1,5</sup> which was based upon an extensive review of the evidence for the antenatal management of twin and triplet pregnancies. An evidence update to this guideline was published in 2013.<sup>6</sup> The proceedings of the 50th RCOG Study Group on Multiple Pregnancy also gave important expert opinion used in this document.<sup>4</sup>

In addition, qualitative information and patient representation has been provided by Mr Keith Reed on behalf of the Twins And Multiple Births Association and Ms Jane Denton on behalf of The Multiple Births Foundation.

Where possible, recommendations are based on available evidence. In the absence of published evidence, these have been annotated as 'good practice points'. Further information about the assessment of evidence and the grading of recommendations may be found in Appendix I.

#### 4. Diagnosis of monochorionic twin pregnancy

##### 4.1 *How is monochorionicity diagnosed prenatally and what is the accuracy of prenatal ultrasound chorionicity allocation?*

**All women with a twin pregnancy should be offered an ultrasound examination between 11<sup>+0</sup> weeks and 13<sup>+6</sup> weeks of gestation (crown–rump length 45–84 mm) to assess fetal viability, gestational age and chorionicity, and to exclude major congenital malformations.**

**B**

**Chorionicity should be determined at the time the twin pregnancy is detected by ultrasound based upon the number of placental masses, the appearance of the membrane attachment to the placenta and the membrane thickness. This scan is best performed before 14 weeks of gestation.**

**D**

**A photographic (thermal copy) record should be taken and placed in the patient's notes documenting the ultrasound appearance of the membrane attachment to the placenta and an electronic copy stored (Appendix II).**

✓

**If there is uncertainty about the diagnosis of chorionicity, a photographic record of the ultrasound appearance of the membrane attachment to the placenta should be retained and a second opinion should be sought.**

✓

**If there is still doubt in the diagnosis of chorionicity, the woman should be referred to a specialist without delay, as chorionicity is best determined before 14 weeks of gestation.**

**D**

**On ultrasound, the fetuses in twin pregnancies should be assigned nomenclature (i.e. upper and lower, or left and right) and this should be clearly documented in the woman's case notes to ensure consistency throughout pregnancy.**

**C**

First trimester ultrasound scanning is important in multiple pregnancies as it confirms viability, determines gestational age, defines chorionicity (by denoting placental mass numbers and membrane thickness), determines the number of amniotic sacs and may identify fetal anomalies (i.e. large cystic hygroma, anencephaly).<sup>1,6</sup> In monochorionic twins, it is also important to exclude 'acardiac twinning', which is associated with TRAP. At this ultrasound examination, screening for Down syndrome may also be offered to couples (see below).

Evidence level 2++

In spontaneously conceived twins, gestational age can be determined at the first trimester scan by using the crown–rump length of the larger fetus to avoid the risk of estimating it from a baby with early growth pathology.

The accurate assessment of chorionicity is more sensitive and specific in the first trimester and it is important to assess and document chorionicity clearly at this gestational age. NICE guidance<sup>1,5,6</sup> indicates that this should be performed at the time of the first trimester scan to screen for Down syndrome. There is significant benefit in identifying women with monochorionic pregnancies early as these pregnancies will require additional fetal surveillance. It also allows women to be fully counselled on the risks and appropriate management of monochorionicity to be implemented. Differentiating between monochorionic and dichorionic pregnancies will result in a saving of time and emotional stress by avoiding unnecessary additional interventions in dichorionic pregnancies.

Evidence level 4

Clinicians should be aware that, although ultrasound assessment of chorionicity is very accurate, it does not have 100% sensitivity. The NICE guideline identified 14 studies investigating diagnostic accuracy of the following characteristics (as determined by an ultrasound scan) for determining chorionicity:<sup>1,5,6,21</sup>

- Number of placental sites and the characteristics of the inter-twin membrane placental insertion (so-called lambda/T-sign) in the first trimester. Approximately 3% of monochorionic placentas have two placental masses (bilobed placenta), so these are not necessarily dichorionic.<sup>22</sup>
- Inter-twin membrane thickness using two-dimensional ultrasound: i) with thickness usually subjectively defined, but in the literature, this is less than 1.8 mm for monochorionic twins; and ii) 1.5–2.0 mm can be inconclusive for monochorionic twins, but when used with other factors, chorionicity can usually be defined in 99% of cases.<sup>23,24</sup>
- The number of membrane layers (subjectively noted).<sup>25</sup>
- Composite measures based on the above characteristics and others (number of placental masses, number of gestational sacs, concordant fetal sex [in monochorionic twins] and number of fetal poles).<sup>1,4–6</sup>

Evidence level 1+

The strongest likelihood ratios were reported for a composite method involving presence of a lambda or T-sign, and noting the number of placental masses identified using ultrasound in the first trimester. Using such criteria, sensitivity and specificity were greater than 95%.<sup>24</sup>

Evidence level 2+

Monochorionic twin pregnancies have a single placental mass and a thin inter-twin membrane that inserts into the placenta at a perpendicular plane (T-sign). In contrast, dichorionic twin pregnancies have two placental masses (or adjacent placental masses forming a 'lambda sign' as placental tissue is present where the thick inter-twin membrane inserts onto the placenta [Appendix II]).<sup>1,5,6</sup>

Evidence level 2++

This assessment should be followed up with noting concordant fetal sex at the midtrimester ultrasound scan.<sup>4</sup>

Evidence level 4

It is sometimes necessary to review the assigned chorionicity of multiple pregnancies in the second or even third trimester. A retained photographic record (either in the patient's handheld notes or stored in the hospital notes) will allow this to be easily reviewed. An archived image should also be stored.

The sensitivity and specificity of ultrasound to define chorionicity is highest before 14 weeks of gestation.<sup>1,23,24</sup> If a trained sonographer, as part of routine first trimester screening, cannot define with confidence the chorionicity of the pregnancy, then a second opinion must be sought from a senior sonographer or the woman should be offered referral to a healthcare professional who is competent in determining chorionicity by ultrasound scan as soon as possible.<sup>1</sup>

Evidence level 3

If it is difficult to determine chorionicity, even after referral (for example, because the woman has booked late in pregnancy), then the pregnancy should be managed as monochorionic until proved otherwise.<sup>1</sup>

Accuracy in labelling monochorionic twins is important so that serial growth scan measurements can be consistently applied to the same twin throughout pregnancy and that any intrauterine or neonatal management can be directed towards the correct twin. A retrospective study<sup>24</sup> found that ascribing labels based on lateral or vertical orientation was a reliable method of twin labelling. This study, based on 416 twin pregnancies, labelled the twin whose gestational sac was closest to the cervix at the 11–14-week scan as ‘twin 1’ and recorded the twins’ orientation as lateral or vertical given their relative positions to each other (left/right or top/bottom, respectively). Approximately 90% of twins were oriented laterally and 10% vertically. The presenting order of 8.5% of the laterally oriented twins changed between the first and last scans; there were no such changes in the vertically oriented pregnancies. Based on a subset of mixed-sex twins ( $n = 108$ ), the presenting order in a third trimester scan was different to the subsequent birth order in 5.9% of pregnancies delivered vaginally and 20.3% of pregnancies delivered by caesarean section.

Evidence level 2+

The authors concluded that recording the twins’ relative position to each other was a reliable method of labelling twin pregnancies compared with designating the babies as ‘twin 1’ and ‘twin 2’, and was conceptually more open to the possibility that the anticipated birth order of the twins might change, especially where delivery is by caesarean section.<sup>24</sup>

## 5. Outcome of monochorionic twin pregnancy

### 5.1 *What is the outcome of monochorionic compared with dichorionic twin pregnancies?*

**Clinicians and women should be aware that monochorionic twin pregnancies have higher fetal loss rates than dichorionic twin pregnancies, mainly due to second trimester loss and, overall, may have a higher risk of associated neurodevelopmental morbidity. This should form part of the parental counselling.**



A prospective Scandinavian study<sup>26</sup> of 495 pregnancies diagnosed before 15 weeks found fetal loss at less than 24 weeks of gestation to be 14.2% in monochorionic compared with 2.6% in dichorionic pregnancies ( $P < 0.05$ ). The number of babies alive at 8 months of age (percentage of fetuses at inclusion) was 82.4% monochorionic compared with 96.3% dichorionic ( $P < 0.01$ ). Mean birthweight (both twins) and mean gestational age at delivery was lower in monochorionic twins ( $P < 0.01$ ). A retrospective study of 1407 twin pregnancies in the Netherlands over a 10-year period found the perinatal mortality rate to be 11.6% in monochorionic twins compared with 5.0% in dichorionic twins. Monochorionic twins continued to be at greater risk even after 32<sup>+0</sup> weeks.<sup>27</sup> A retrospective study of all twin pregnancies of known chorionicity from a large regional cohort of nine hospitals over a 10-year period in south London has indicated an

Evidence level 2+

increased fetal loss rate prior to 24<sup>+0</sup> weeks in monochorionic twins (60.3/1000 fetuses) compared with dichorionic twins (6.6/1000 fetuses) and that this risk continues through pregnancy as risk of stillbirth after 26<sup>+0</sup> weeks.<sup>28,29</sup> This has been confirmed by several studies in different parts of the world.<sup>30,31</sup>

Evidence level 2+

In addition, neurological morbidity may be up to seven-fold higher in preterm monochorionic infants compared with dichorionic infants due to associated complications of TTTS, sGR and single twin death in utero.<sup>32,33</sup>

## 6. Optimal screening for chromosomal abnormalities, structural abnormalities and other fetal complications in monochorionic twin pregnancies

### 6.1 What is the optimum method of screening for chromosomal abnormalities in monochorionic twin pregnancies?

**Women with monochorionic twins who wish to have aneuploidy screening should be offered nuchal translucency measurements in conjunction with first trimester serum markers (combined screening test) at 11<sup>+0</sup> weeks to 13<sup>+6</sup> weeks of gestation (crown–rump length 45–84 mm).**

C

**In women with monochorionic twin pregnancies who ‘miss’ or who have unsuccessful first trimester screening for aneuploidy, second trimester screening by the quadruple test should be offered.**

D

**Early data with noninvasive prenatal testing (NIPT) are encouraging, but results should be interpreted with caution until larger studies have been carried out.**

C

Monochorionic twins are not at increased risk of chromosomal abnormalities over dichorionic twins, but the prevalence of aneuploidy is slightly increased overall in multiple pregnancies because of an indirect association with increased maternal age.<sup>1,4</sup>

Evidence level 3

First trimester combined screening using nuchal translucency and the serum analytes of free beta-human chorionic gonadotrophin and pregnancy-associated plasma protein A (combined test screening) should be offered to pregnant women with monochorionic twins at a crown–rump length of between 45 and 84 mm.<sup>1</sup> This screening test has good sensitivity for detecting aneuploidy (90%), but the false-positive rate (up to 10%) is higher than in singletons (2.5%) and dichorionic twins (5%).<sup>1</sup>

Evidence level 2+

When screening is performed by nuchal translucency, first trimester serum screening and maternal age, a pregnancy-specific risk is calculated in monochorionic twins. This is in contrast to dichorionic twins in whom a fetus-specific risk is calculated.<sup>1,34</sup>

Approximately 10% of pregnant women do not have their first antenatal booking appointment in the first trimester. If the gestation at first visit is after 14 weeks, then second trimester serum screening should be offered using the quadruple screen test (with an 80% detection rate and a false-positive rate of 3%) so as to not disadvantage these women. This screening test in monochorionic twins provides a pregnancy-specific risk.<sup>1,35</sup>

Evidence level 3

NIPT for fetal trisomy 21 risk assessment is now available and is rapidly replacing other screening tests. In singleton pregnancy, it has a much higher detection rate and lower false-positive rate than the current best screening tests (i.e. combined nuchal translucency screening). In a 2014 meta-analysis, the weighted pooled detection rate for trisomy 21 in singleton pregnancies was 99% for a false-positive rate of 0.8%.<sup>36</sup> The corresponding values in twin pregnancies were 94.4% and 0%. However, the reported number of trisomy 21 cases in the twin pregnancies included was small (three studies; 18 cases). Since this meta-analysis, two more publications have reported promising detection rates.<sup>37,38</sup> The largest published study<sup>38</sup> comparing NIPT in twins versus singletons (515 twin pregnancies versus 1847 singletons) demonstrated that failed test rates (failure to get a result) were higher compared with singletons (5.6% versus 1.7%). The studies do not differentiate detection rates and failed test rates according to chorionicity. As in monozygotic twinning the fetuses share the same genetic material in the vast majority of cases (i.e. are genetically identical), the performance of NIPT should be similar to that in singletons. Clinicians should be aware of the latest guidance from the National Screening Committee.

Evidence level 1+

Please see section 11 for invasive diagnostic testing in twin pregnancy.

## 6.2 *What is the optimum method of screening for structural abnormalities in monozygotic twin pregnancies?*

**All monozygotic twins should undergo a routine detailed ultrasound scan between 18 and 20<sup>+6</sup> weeks of gestation which includes extended views of the fetal heart anatomy (as recommended in the Fetal Anomaly Screening Programme screening of a singleton fetus).**



Structural abnormalities, particularly cardiac abnormalities, are more common in twin and higher order pregnancies than in singleton pregnancies. This is mainly because of the higher incidence of abnormalities in monozygotic twins (owing to the unusual nature of the cleavage of the conceptus) compared with dizygotic twins.<sup>39</sup> Monozygotic twins are monozygotic in 70% of cases; hence the higher rates of abnormality in monozygotic twins. Abnormalities specific to monozygotic twins are often midline (such as holoprosencephaly, neural tube defects and cardiac abnormalities).<sup>39</sup> As one cannot determine monozygosity using ultrasound, both monozygotic and dichorionic twins have the same recommended second trimester ultrasound screening regimen, which is in line with the NICE guideline.<sup>1,6</sup>

Evidence level 4

A Scandinavian study of twin pregnancies<sup>26</sup> where women had a package of scans (nuchal translucency scan, anomaly scan at 19 weeks of gestation, fetal echocardiography at 21 weeks of gestation and a cervical length scan at 23 weeks of gestation) found that 0.5% of the fetuses had cardiac anomalies, 80% of which were detected at the 19–20-week anomaly scan (i.e. before fetal echocardiography) and therefore, concluded that formal fetal echocardiography by a cardiologist is not justified.

Evidence level 2+

Limited published evidence suggests that detection rates of fetal anomalies on ultrasound scan for twin pregnancies are similar to published data for singletons.<sup>26,40–42</sup> Therefore, routine anomaly screening by a trained screening sonographer between 18 and 20<sup>+6</sup> weeks of gestation is appropriate<sup>1,43</sup> and should include extended cardiac views as per the NHS Fetal Anomaly Screening Programme current screening protocols.<sup>43</sup>

Evidence level 4

The management of monozygotic pregnancies where one fetus has a congenital abnormality is complex because of shared circulations within the placenta. Timely diagnosis facilitates management by allowing time to prepare,



optimisation of fetal surveillance depending on the anomaly, involvement of multidisciplinary specialists (e.g. genetics team, paediatric cardiologist, paediatric surgeons) and appropriate birth planning (place, timing and mode), including access to intrauterine management where it is possible. Management of discordant abnormalities is addressed in section 11.

Selective termination of a single fetus in a monochorionic pregnancy should be assessed and carried out in a centre with expertise and experience in performing such prenatal procedures. In addition, increased prenatal surveillance, the potential for referral to a tertiary specialist centre and the adverse risks to the pregnancy must be discussed in a timely fashion.

### 6.3 *What is the optimum ultrasound regimen for monochorionic twin pregnancies?*

**Fetal ultrasound assessment should take place every 2 weeks in uncomplicated monochorionic pregnancies from 16<sup>+0</sup> weeks onwards until delivery (Appendix III).**



**At every ultrasound examination, liquor volume in each of the amniotic sacs should be assessed and a deepest vertical pocket (DVP) depth measured and recorded, as well as the umbilical artery pulsatility index (UAPI). Fetal bladders should also be visualised. Although first presentation of TTTS is rare after 26<sup>+0</sup> weeks of gestation, it can occur and therefore, scans should be performed at 2-weekly intervals in uncomplicated monochorionic twins until delivery (Appendix III).**



**From 16<sup>+0</sup> weeks of gestation, fetal biometry should be used to calculate an EFW and the difference in EFW calculated and documented. As the risk of sGR extends to delivery, this should be performed at 2-weekly intervals until delivery.**



There are a number of serious pathologies in monochorionic twin pregnancy that need to be screened for routinely. Ultrasound is required to make these diagnoses and therefore, serial ultrasound is required at regular intervals.

Ultrasound examinations between 16 and 26 weeks of gestation focus primarily on the detection of TTTS.<sup>1</sup> After 26 weeks, when first presentation of TTTS is relatively uncommon (but may occur), the main purpose is to detect sGR or concordant growth restriction, and more rarely TAPS or late-onset TTTS. The 2011 NICE guideline suggested that surveillance of uncomplicated monochorionic twins should occur at intervals of every 2 weeks from 16<sup>+0</sup> weeks of gestation until delivery.<sup>1</sup> One of the prime reasons for performing serial ultrasound scans in monochorionic twins between 16 and 26 weeks is to detect TTTS. Thus, the development of discordance in liquor volumes within the amniotic sacs is pivotal to the process of detection and diagnosis.<sup>44</sup> After 26 weeks, TTTS may still occur and in addition, sGR may also be associated with discordant liquor volumes. For this reason, this guideline has been modified to include the recommendation that ultrasound surveillance is performed from 16 weeks until delivery at 2-weekly intervals. This is different from the NICE guidance published in 2011 (but undergoing revision).

Evidence level 2+

There are no comparative studies of assessment techniques or regimens to assess fetal growth and wellbeing, and to detect late-onset TTTS (after 26 weeks). Few twin pregnancies were included in the randomised trials of umbilical artery Doppler velocimetry to detect FGR and these were not specifically monochorionic.<sup>45</sup>

Evidence level 2–

Since 2011,<sup>1</sup> the international research community has evaluated the risk of other complications, especially sGR, and it is now recommended that, in addition to screening for TTTS, from 20 weeks of gestation, screening for sGR should be included.<sup>19</sup>

This ultrasound screening should include, as a minimum, fetal biometry measurements (head, abdominal and femur measurements), measurement and recording of DVP depth of both sacs, and evaluation of fetal bladders (i.e. size and visibility). From 16<sup>+0</sup> weeks of gestation, EFW should be calculated and documented (Appendix III). In addition, if at any point in time there is evidence of significant growth discordance or a suspicion of TTTS, then UAPI, middle cerebral artery peak systolic velocity (MCA PSV) and pulsatility index, and ductus venosus Dopplers should be performed. From 16 weeks of gestation, umbilical artery Doppler velocities should be evaluated, and the presentation of positive, absent or reversed velocities noted and documented. From 20 weeks of gestation, UAPI should be performed even in the absence of signs of TTTS or growth discordance (uncomplicated monochorionic twins) and plotted on standard charts. This may be best performed in a multiple pregnancy clinic.

The STORK population-based data set was analysed to evaluate fetal biometry in the second and third trimesters of 323 monochorionic twin pregnancies. It was found that ultrasound biometry showed 'a small but statistically significant reduction in fetal growth in twin pregnancies relative to that in singletons, particularly in the third trimester, with a more marked difference for MCDA than for dichorionic diamniotic (DCDA) pregnancies'.<sup>46</sup> For each variable, the mean value for DCDA twins was close to the reported value in singletons at 20–30 weeks of gestation and showed a decrease relative to singletons beyond 30 weeks. Fetuses in MCDA twin pregnancies displayed lower mean measurements than those in DCDA pregnancies throughout the gestational age range considered. In addition, this group found that algorithm formulas for calculation of EFW that include a combination of head, abdomen and femur measurements perform best in both singleton and twin pregnancies (Hadlock 2 formula).<sup>47</sup>

Evidence level 2+

#### 6.4 *What are the optimum methods of screening for specific complications of monochorionic twin pregnancies?*

##### 6.4.1 Screening for TTTS

**Screening for TTTS by first trimester nuchal translucency measurements should not be offered.**



**Women with monochorionic twin pregnancies should be asked to report sudden increases in abdominal size or breathlessness to healthcare professionals in their secondary or tertiary centres as this may be a manifestation of TTTS.**



**Screening for TTTS should be by ultrasound examination from 16<sup>+0</sup> weeks onwards, at 2-weekly intervals, noting and recording fetal biometry and liquor volumes (DVP). Fetal bladders should also be visualised.**



A large, prospective, Scandinavian, five-centre study that reported on 74 monochorionic pregnancies diagnosed before 15 weeks of gestation<sup>26</sup> did not find that measurement of nuchal translucency predicted the development of TTTS. Women with monochorionic pregnancies were scanned every 2 weeks between 12 and 23 weeks of gestation to detect TTTS. DNA testing was used to assess zygosity after delivery. TTTS was diagnosed in 23% of monochorionic pregnancies. Nuchal translucency measurements were not helpful in predicting TTTS.

Evidence level 2++

Unfortunately, common symptoms of twin pregnancy overlap with those associated with pathological conditions, such as TTTS. Many women with TTTS indicate that several weeks before presentation they note an increase in symptoms of breathlessness and abdominal distension. Pregnant women with monochorionic twins should have a low threshold for presenting to healthcare professionals with concerns. This should be discussed by healthcare professionals at their first booking visit.

The ultrasound diagnosis of TTTS is based on the following criteria (see Table 1):

- Significant amniotic fluid discordance. This is the key to the diagnosis: there must be oligohydramnios with DVP less than 2 cm in one sac (the donor) and polyhydramnios in the other sac (DVP more than 8 cm before 20 weeks of gestation and more than 10 cm after 20 weeks of gestation) (the recipient).<sup>48–50</sup>
- Discordant bladder appearances – with no urine in the ‘donor’ fetal bladder in severe TTTS (presenting before 26 weeks of gestation).
- Haemodynamic and cardiac compromise – both in the ‘recipient’ and/or ‘donor’ twins.

Evidence level 2–

In most centres, treatment for TTTS would not start until 16 weeks of gestation and therefore, first trimester screening was evaluated as having little benefit over initiating ultrasound scans at 16 weeks of gestation in apparently uncomplicated monochorionic twins.<sup>1,6</sup>

Evidence level 4

For ultrasound screening in the second trimester, several studies reported that inter-twin membrane folding (usually with less severe amniotic fluid discordance) predicted TTTS later in gestation.<sup>19,44,48</sup> Twins below 20 weeks of gestation with an amniotic fluid discordance (from DVP depth) of 3.1 cm or more had a risk of TTTS of 85.7%. Sensitivity for diagnosis of TTTS was 55%. An inter-twin EFW discordance of 25% or more had 63% sensitivity and 76% specificity for sGR without TTTS.<sup>48</sup> If there is liquor volume discordance in monochorionic twins that does not reach the ‘threshold’ for the diagnosis of TTTS, management should be individualised with a high degree of vigilance.

Evidence level 2–

No studies were identified in relation to using femur length, abdominal circumference, EFW, ultrasonography of placental anastomoses, tricuspid regurgitation or absent visualisation of a donor bladder to predict the development of TTTS.

#### 6.4.2 Screening for TAPS

**TAPS should be screened for following fetoscopic laser ablation for TTTS and in other complicated monochorionic pregnancies requiring referral to a fetal medicine centre (such as those complicated by sGR) by serial MCA PSV.**



TAPS is a form of TTTS characterised by a significant discordance in haemoglobin level between twins without significant amniotic fluid discordance.<sup>16–18</sup> This can be diagnosed by the presence of increased MCA PSV in the donor, suggestive of fetal anaemia (greater than 1.5 multiples of the normal median), and a decreased MCA PSV in the recipient twin, suggestive of polycythaemia (less than 1.0 multiples of the normal median), with the absence of significant oligohydramnios/polyhydramnios sequence.<sup>18</sup> TAPS may occur spontaneously in up to 2%<sup>17,18</sup> of monochorionic twins and in up to 13% following fetoscopic laser for TTTS.<sup>15,51</sup>

Evidence level 2–

The placentas in monochorionic pregnancies complicated by TAPS are characterised by the presence of only a few minuscule artery–vein vascular anastomoses. These small anastomoses allow a slow transfusion of blood from the donor to the recipient, leading progressively to a significant discordance in haemoglobin levels. The absence of severe amniotic fluid discordances in TAPS may be related to the very slow inter-twin blood transfusion, allowing more time for haemodynamic compensatory mechanisms to take place.<sup>16–18</sup>

Evidence level 3

Because TAPS mainly occurs in complicated cases and because there is little evidence to guide management (see section 7.3), screening of monochorionic twins for TAPS using serial MCA PSV measurements is not routine and should be confined to complicated monochorionic twin pregnancy where the risk of TAPS is high (those with TTTS or sGR). Further prospective research evaluating the role of undertaking MCA PSV screening in monochorionic twin pregnancies routinely to detect TAPS and to improve pregnancy outcome is required.

Postnatal diagnosis of TAPS is based on the presence of (chronic) anaemia in the donor (including reticulocytosis) and polycythaemia in the recipient. Postnatal haematological criteria include an inter-twin haemoglobin difference greater than 80 g/l and a reticulocyte count ratio greater than 1.7.<sup>18,52</sup>

Evidence level 3

### 6.4.3 Screening for sGR

**At each scan from 20 weeks of gestation (at 2-weekly intervals) onwards, calculate EFW discordance using two or more biometric parameters. Calculate percentage EFW discordance using the following formula:  $[(\text{larger twin EFW} - \text{smaller twin EFW}) / \text{larger twin EFW}] \times 100$ . Liquor volumes as DVP should be measured and recorded (to differentiate from TTTS).**

C

**An EFW discordance of greater than 20% is associated with an increase in perinatal risk. Such pregnancies should be referred for assessment and management in fetal medicine units with recognised relevant expertise.**

B

**Umbilical artery Doppler evaluation in monochorionic twins with sGR allows definition of prognosis and potential morbidity. In particular, those with absent or reversed end-diastolic velocities (AREDV) and ‘cyclical’ umbilical artery Doppler waveforms (intermittent AREDV [iAREDV]) are at increased risk of perinatal mortality and morbidity (Appendix IV).**

C

Unequal placental sharing, and marginal or velamentous cord insertions are common in monochorionic twins and can result in discordant fetal growth, where one fetus is usually normal size and the other small for gestational age (defined as EFW less than the tenth centile). However, even if both fetuses have an EFW greater than the tenth centile there may be significant size discordance. This is termed sGR.<sup>53–56</sup>

Evidence level 2+

sGR is encountered in approximately 10–15% of all monochorionic multiple pregnancies. The pathophysiology and natural history of this condition is different to growth discordance in dichorionic multiple pregnancy. The prospective diagnosis initially may be difficult as there may be diagnostic ‘overlap’ between mild TTTS and sGR. Amniotic liquor volumes (DVP) in TTTS may differ between the fetuses because of polyhydramnios in one of the amniotic sacs and oligohydramnios in the other amniotic sac (but sGR may also be present). However, in isolated sGR this will differ as there is commonly oligohydramnios in one of the amniotic sacs and normal liquor in the other amniotic sac.<sup>53,57</sup>

Evidence level 3

Poor in utero growth of both twins may reflect multifactorial causes, such as maternal factors resulting in global uteroplacental dysfunction, whereas discordant twin growth may be attributed to differences in genetic potential between co-twins, placental dysfunction confined to one placenta only or one placental territory within a shared placenta.<sup>53</sup> In addition, TTTS represents a distinct entity of which discordant growth is a common feature.<sup>53,57</sup>

Evidence level 2+

Discordant growth is recognised as an independent risk factor for adverse perinatal outcome in monochorionic twins and is associated with a substantial increase in perinatal mortality and morbidity for both twins.<sup>53,58</sup> Clinical evolution depends on the combination of the effects of placental insufficiency in the growth-restricted twin with inter-twin blood transfer through placental anastomoses.<sup>53,57</sup>

It appears that a calculated difference in EFW is a sensitive method of defining sGR and appears to be linked with adverse outcome when this is significantly different (see below). The ultrasonic methods used to estimate fetal weight appear to be equally accurate, but one study favoured formulas that include a combination of head, abdomen and femur measurements.<sup>47,54,55</sup>

A prospective study from Ireland noted that perinatal mortality, individual morbidity and composite perinatal morbidity are all seen to increase with birthweight discordance exceeding 18% for monochorionic twins without TTTS (hazard ratio 2.6, 95% CI 1.6–4.3;  $P < 0.001$ ); a minimum two-fold increase in risk of perinatal morbidity exists even when both twin birthweights are appropriate for gestational age.<sup>56</sup> However, others have studied monochorionic and dichorionic twins and noted that prenatal risk does not increase until the difference in EFW is greater than 25%.<sup>1,54</sup>

Evidence level 2+

A 2013 review, performed by leading international researchers in this area, has advocated a compromise ‘cut-off’ of a difference in EFW of greater than 20% for monochorionic twins.<sup>19</sup> This is the pragmatic definition used by this guideline (recognising data of increasing perinatal loss at a percentage EFW difference of 18% from the Irish Consortium).

Evidence level 2++

Umbilical artery waveforms in monochorionic twins with sGR may reflect adverse prognosis for the pregnancy.<sup>45,59</sup> For this reason, the guideline recommends that umbilical artery Doppler pulsatility index measurements are taken from 20 weeks of gestation and plotted on gestational nomogram charts (with umbilical artery Doppler velocities noted to have positive or AREDV from 16 weeks). Doppler

Evidence level 2+

waveforms may demonstrate positive diastolic velocities (type I), AREDV (type II) or cyclical diastolic waveforms (type III), with an attendant worsening of prognosis for perinatal mortality and morbidity. iAREDV on umbilical artery Doppler velocity assessment are more common in MCDA sGR (45%) than uncomplicated (5%) pregnancies or those complicated by severe TTTS (2%).<sup>57,59</sup> This condition appears to result from large artery–artery anastomoses.

Evidence level 2+

sGR type I (Table 1) is associated with a relatively good outcome (more than 90% perinatal survival). Type II sGR is associated with a high risk (up to 29%) of intrauterine demise of the growth-restricted twin and/or preterm delivery. Type III sGR is associated with a 10–20% risk of unexpected fetal demise of the smaller twin (even if stable ultrasound features and/or normal computerised cardiotocography [CTG] hours or days before) and a 10–20% risk of neurological injury in the larger twin.<sup>53,57,59</sup>

## 7. Management of complex pathologies associated with a monochorionic twin pregnancy

### 7.1 The management of TTTS

#### 7.1.1 How useful are grading systems for severity of TTTS in establishing prognosis?

**At diagnosis, TTTS should be staged using the Quintero system. In addition, measurement of umbilical artery Doppler velocities, MCA PSV and ductus venosus Doppler studies should be performed and documented.**

D

The Quintero system of staging TTTS (Table 1) has some prognostic value, but the course of the condition is unpredictable and may involve improvement or rapid deterioration within a short time span.<sup>60–62</sup>

In a series of 173 pregnancies complicated by TTTS from three centres in the USA and Australia, where treatment was either by amnioreduction or selective laser ablation, the outcome of at least one neonatal survivor was 91% (stage I), 88% (stage II), 67% (stage III) and 50% (stage IV).<sup>50,60</sup> Similar findings were reported from Germany in a series of 200 TTTS pregnancies treated by laser ablation: at least one neonatal survivor in 93% (stage I), 83% (stage II), 83% (stage III) and 70% (stage IV).<sup>63</sup>

Many reports of TTTS are difficult to interpret because of referral bias. A study from western Australia is valuable because it is population based, coming from the sole perinatal tertiary service in this Australian state.<sup>60</sup> A prospective cohort of 71 women with TTTS was treated with amnioreduction or septostomy. There was a relationship between Quintero stage at diagnosis and mean gestational age at delivery and perinatal survival: stage I, 32 weeks of gestation, 77% survival; stage II, 31 weeks of gestation, 70% survival; stage III, 28 weeks of gestation, 54% survival; and stage IV, 27 weeks of gestation, 44% survival. However, disease progression was often unpredictable, with 28% of pregnancies improving, 35% worsening and 37% remaining in the same grade throughout gestation. Pregnancies appeared, for example, to progress from stage I to stage III without obviously passing through stage II. Very similar findings came from a smaller cohort study in the USA (n = 18).<sup>61</sup> There were similar rates of regression and progression. Another study found a change of stage with time to be of greater prognostic significance than the stage itself<sup>62</sup> and others in a research setting have found recipient cardiac diastolic function to be important in long-term prognosis.<sup>64,65</sup>

Evidence level 2+

Amniotic fluid discordance, without fulfilling the 8 cm/2 cm criteria (i.e. within the 'normal range'), together with normal umbilical artery Doppler velocimetry is associated with good outcome (93% overall survival) and low risks of progression to severe TTTS (14%).<sup>48,66</sup>

There is controversy about the Quintero staging of TTTS, since stage I disease may not necessarily be associated with the best outcome and indeed recipient twins within stage I TTTS may have evidence of cardiac dysfunction.<sup>67</sup>

To emphasise this, a cross-sectional study from a single centre in the USA has indicated that monochorionic twin pregnancies complicated by TTTS as mild as Quintero stages I and II have a significant proportion of recipient twins with ventricular hypertrophy (17/28; 61%), atrioventricular valve regurgitation (6/28; 21%) and objective abnormalities in either right (12/24; 50%) or left (14/24; 58%) ventricular function<sup>64</sup> at fetal echocardiography. The suggestion that structural and/or functional assessment of the fetal heart (especially in the recipient) by echocardiography of monochorionic pregnancies at risk of or with TTTS may be useful in defining the prognostic risk of severe TTTS and treatment modalities, such as fetoscopic laser ablation,<sup>64,65</sup> are of interest.

Evidence level 2+

### 7.1.2 What is (are) the optimal treatment(s) of TTTS and their outcomes?

**TTTS should be managed in conjunction with fetal medicine centres with recourse to specialist expertise and treatment in supraregional centres.**



**TTTS presenting before 26 weeks of gestation should be treated by fetoscopic laser ablation rather than amnioreduction or septostomy. There is evidence that the fetoscopic laser ablative method should be the Solomon technique.**



**Centres performing fetoscopic laser ablation should perform at least 15 procedures per year (rolling 3-year average).**



**Weekly ultrasound assessment (including examination of the fetal brain, heart and limbs) and serial measurements of UAPI, MCA PSV and ductus venosus Doppler velocities should be performed. After 2 weeks post treatment, the ultrasound interval can be increased to every 2 weeks (noting UAPI, MCA PSV and DVP) with documentation of adequate fetal growth (by calculating EFW).**



**In treated TTTS pregnancies, ultrasound examination of the fetal heart should be performed by the fetal medicine specialist to exclude functional heart anomalies.**



TTTS is a morbid complication of monochorionic twin pregnancies.<sup>4</sup> Once there is a suspicion of the disease or the diagnosis has been prospectively made using ultrasound, the pregnancy should be managed in conjunction with a fetal medicine centre, with specialists that perform treatment of the condition, including fetoscopic laser ablation. This is in concordance with the national commissioning guidance for the management of this condition in England.<sup>68</sup>

Evidence level 4

There are supraregional centres in the UK that will offer fetoscopic laser ablation for TTTS. Each case should be managed on an individual basis, but commonly, this treatment is for Quintero stage II or more and many will treat this condition if there is Quintero stage I with significant polyhydramnios (8 cm or more) or cervical shortening (less than 25 mm).<sup>4</sup>

The Eurofetus consortium trial randomised women with TTTS to either laser ablation or amnioreduction.<sup>69</sup> The planned sample size of 172 women aimed to demonstrate a 15% difference in survival. The large majority of women had Quintero stage II or III TTTS. Three women in the laser group did not undergo the procedure. Two women in the amnioreduction group did not undergo the procedure and seven underwent laser ablation, six following amnioreduction. As compared with the amnioreduction group, the laser group had a significantly higher likelihood of the survival of at least one twin to 28 days of age and 6 months of age. Infants in the laser group also had a lower incidence of cystic periventricular leukomalacia and were more likely to be free of neurological complications at 6 months of age. The authors' conclusion was that fetoscopic laser coagulation of anastomoses is a more effective first-line treatment than serial amnioreduction for severe TTTS diagnosed before 26 weeks of gestation.

Another randomised trial compared amnioreduction with septostomy (the deliberate creation of a hole in the dividing septum with the intention of improving amniotic fluid volume in the donor sac).<sup>70</sup> The trial included 73 women with TTTS (of all stages). The primary outcome was at least one infant surviving until hospital discharge. The trial was stopped after an interim analysis because no significant differences were seen in the primary outcome.

The results of a third study, the National Institute of Child Health and Human Development trial of amnioreduction versus laser ablation,<sup>71</sup> have been added to the Cochrane review on the topic.<sup>72</sup> In this randomised controlled trial, pregnancies with severe TTTS were only entered into the study after a 'test' amnioreduction. This may have produced bias in the study. This trial noted that there was no statistically significant difference in 30-day postnatal survival between laser ablation and amnioreduction treatment for donors at 55% (11/20) versus 55% (11/20) ( $P = 1.0$ ; OR 1, 95% CI 0.242–4.14) or recipients at 30% (6/20) versus 45% (9/20) ( $P = 0.51$ ; OR 1.88, 95% CI 0.44–8.64). There was no difference in 30-day survival of one or both twins on a per pregnancy basis between amnioreduction at 75% (15/20) and laser ablation at 65% (13/20) ( $P = 0.73$ ; OR 1.62, 95% CI 0.34–8.09). Overall survival (newborns divided by the number of fetuses treated) was not statistically significant for amnioreduction at 60% (24/40) versus laser ablation at 45% (18/40) ( $P = 0.18$ ; OR 2.01, 95% CI 0.76–5.44). There was a statistically significant increase in fetal recipient mortality in the laser ablation arm at 70% (14/20) versus the amnioreduction arm at 35% (7/20) ( $P = 0.25$ ; OR 5.31, 95% CI 1.19–27.6). This was offset by an increased recipient neonatal mortality of 30% (6/20) in the amnioreduction arm.

Evidence level 1+

The results of the three studies have been reanalysed in a Cochrane review, adjusting where possible for clustering, recognising the nonindependence of twin fetuses within a pair.<sup>72</sup>

The conclusion of the Cochrane review was that endoscopic laser coagulation of anastomotic vessels should continue to be considered in the treatment of all stages of TTTS to improve neurodevelopmental outcomes in the child. When compared with amnioreduction, treatment with laser coagulation does not appear to increase or reduce the risk of overall death (stillbirth, neonatal and postneonatal) in this condition, but it appears to result in more children being alive without neurological abnormality.<sup>72</sup>

Amnioreduction can be retained as a treatment option for those situations where the expertise for laser coagulation is not available, pending transfer to a unit where such treatment can be obtained or when the condition is diagnosed after 26 weeks of pregnancy. However, this may complicate future treatment if associated with inadvertent septostomy.<sup>72</sup>



Randomised evaluation of interventions, such as septostomy, serial amniocentesis and placental laser ablation, with regard to their respective effect on relatively mild forms of TTTS (Quintero stage I) and more severe forms (Quintero stage IV) are required.<sup>72</sup> However, there is some evidence that fetoscopic laser ablation is the best treatment of TTTS in early-onset (less than 17 weeks) and late-onset (after 26 weeks) disease.<sup>73,74</sup>

Evidence level 3

Anastomoses may be missed at fetoscopic laser ablation and this is the most common cause of recurrence and morbidity.<sup>9,15</sup> Recurrent TTTS can occur in up to 14% of pregnancies treated with fetoscopic laser ablation and be associated with or without TAPS.<sup>15,51</sup> Such outcomes are associated with a worsening of neonatal morbidity. There is randomised controlled trial evidence that modification of the primary fetoscopic laser technique by 'equatorial laser dichorionization' (or the Solomon technique) significantly reduces these complications of recurrent TTTS and TAPS.<sup>15</sup>

Evidence level 1+

Fetoscopic laser ablation can be performed in monochorionic and dichorionic (triamniotic) triplet pregnancies, but the placental angioarchitecture is usually more complex and the perinatal outcomes are in general poorer than in the treatment of twins.<sup>75,76</sup>

Evidence level 3

Some women request termination of pregnancy when severe TTTS is diagnosed and this should be discussed as an option. Another option is to offer selective termination of pregnancy using bipolar diathermy of one of the umbilical cords or using radiofrequency ablation, with inevitable sacrifice of that baby.<sup>77,78</sup> This may be appropriate, for example, if there is evidence of cerebral damage in either twin.<sup>79</sup>

There are few data to inform how frequently ultrasound surveillance is required after fetoscopic laser ablation (or amnioreduction). Following laser treatment, the recurrence rate is up to 14%, which is likely to be secondary to missed anastomoses at the time of initial laser treatment.<sup>15</sup> However, most experts advocate that ultrasound examination (with brain imaging, fetal measurement and Doppler assessment, especially of the MCA PSV) should be performed every week for the first 2 weeks and then every other week following clinical resolution. TAPS may complicate post fetoscopic laser ablation in up to 13% of cases (the most common complication after fetal demise). Therefore, at these ultrasound examinations, MCA PSV should be performed and the result recorded.

Evidence level 2+

However, some have indicated that functional cardiac studies may add to the prognosis of MCDA twins complicated by TTTS.<sup>64,65,67</sup> In a case series of 89 survivors from 73 pregnancies treated by laser ablation for severe TTTS, 11% of fetuses had secondary, structural heart disease, primarily right-sided cardiac lesions, predominantly pulmonary stenosis.<sup>63</sup>

Evidence level 2–

### 7.1.3 When should the delivery of monochorionic twin pregnancies complicated by TTTS take place?

**Delivery of monochorionic twin pregnancies previously complicated by TTTS and treated should be between 34<sup>+0</sup> and 36<sup>+6</sup> weeks of gestation.**

D

International expert opinion has indicated that, even after successful treatment, regular ultrasound surveillance should be routine and good practice.<sup>19,80</sup> Consideration should be given to delivery of the surviving twin(s) between 34<sup>+0</sup> and 36<sup>+6</sup> weeks,<sup>4,80,81</sup> or earlier if there are concerns. As with previous RCOG and NICE guidance, prophylactic maternal steroids should be given if possible prior to delivery. Mode of delivery can be individualised, but often this is by caesarean section.<sup>82</sup>

Evidence level 2–

## 7.2 The management of sGR

sGR in monochorionic twins requires evaluation in a fetal medicine centre with expertise in the management of such pregnancies.



In cases of early-onset sGR in association with poor fetal growth velocity and abnormal umbilical artery Doppler assessments, selective reduction may be considered an option.



In sGR, surveillance of fetal growth should be undertaken at least every 2 weeks with fetal Doppler assessment (by umbilical artery and middle cerebral artery pulsatility index, and peak systolic velocity). If umbilical artery Doppler velocities are abnormal, the Doppler assessments should be undertaken in line with national guidance, measuring ductus venosus waveforms.



Clinicians should be aware that there is a longer 'latency period' between diagnosis and delivery in monochorionic twins complicated by sGR compared with growth restriction in dichorionic twin pregnancy or singleton pregnancy.



Abnormal ductus venosus Doppler waveforms (reversed flow during atrial contraction) or computerised CTG short-term variation should trigger consideration of delivery.



In type I sGR, planned delivery should be considered by 34–36 weeks of gestation if there is satisfactory fetal growth velocity and normal umbilical artery Doppler waveforms.



In type II and III sGR, delivery should be planned by 32 weeks of gestation, unless fetal growth velocity is significantly abnormal or there is worsening of the fetal Doppler assessment.



It is important to prospectively inform parents that in sGR and TTTS (even after apparently successful treatment) there can be acute transfusional events (which are neither predictable nor preventable) and therefore, despite regular monitoring, there may still be adverse perinatal outcomes.



Once there is a suspicion of sGR or the diagnosis has been prospectively made using ultrasound, the pregnancy should be managed in conjunction with a regional fetal medicine centre with specialist expertise in managing this condition. There is a need to measure amniotic sac liquor volumes and to assess Doppler velocities within the fetal arterial and venous circulations.<sup>53,57,59</sup>

Evidence level 4

Umbilical artery Doppler evaluation in monochorionic twins with sGR allows the prospective definition of three subtypes (see Table 1)<sup>53,57,59</sup> and the consequences are dependent upon this evaluation and gestational age.

Evidence level 3

When sGR is diagnosed such that the difference in EFW is greater than 20%, fetal and perinatal loss is increased.<sup>19,56</sup> Prior to viability (24 weeks), if the small twin has a significantly reduced fetal growth velocity (change in measured abdominal circumference of less than 1 SD over 14 days) in the presence of umbilical artery Doppler abnormalities, there is a significant risk of single fetal demise.<sup>59</sup>

Evidence level 2+

In such circumstances, to protect the appropriately grown co-twin, selective termination of pregnancy using vaso-occlusive techniques, such as bipolar cord occlusion or radiofrequency ablation may be considered.<sup>79,83</sup> This should be assessed and performed in a tertiary centre with expertise. Again, informed but sensitive discussion with patients is mandatory.

Evidence level 2+

There is limited evidence to guide clinical care in these complex cases. However, there is international consensus that such monochorionic twin pregnancies require regular review with interval ultrasound biometry to monitor fetal growth velocity, and placental and fetal circulation assessment by umbilical artery, middle cerebral artery and ductus venosus Doppler waveform measurements.<sup>53,57,59,84</sup> The aim is to prolong pregnancy to at least viability and to achieve appropriate gestation for delivery (32–34 weeks), but to avoid the complication of single fetal death and the consequences for the surviving fetus.<sup>53</sup>

Evidence level 2–

Timing of delivery (less than 32 weeks of gestation) is dependent upon assessment by computerised CTG and/or ductus venosus waveform velocimetry. For monochorionic twin sGR where there is umbilical Doppler abnormality, delivery should be undertaken at 32 weeks (in line with singleton FGR with AREDV).<sup>85</sup>

Evidence level 2++

The placental anastomoses in monochorionic twins paradoxically may be beneficial for the smaller twin as transfusion from the larger twin may compensate for the placental insufficiency, thus interfering with the natural history in comparison with singleton and dichorionic twin pregnancies. This is also associated with the presence of artery–artery anastomoses. This prolongs survival in the growth-restricted fetus, resulting in a longer latency period to deterioration and delivery (up to 10 weeks versus 3–4 weeks from diagnosis of FGR).<sup>8</sup>

Evidence level 3

In monochorionic twins, where the placental vascular anastomoses remain intact, there is a risk of acute ‘inter-twin’ transfusional events causing fetal death and morbidity in the form of neurological morbidity. This is true of apparently uncomplicated monochorionic twins, but more prevalent in monochorionic twins complicated by sGR and even treated TTTS.<sup>1,4</sup>

### 7.3 Management of TAPS

**Clinicians should be aware that the natural history, fetal and neonatal implications, and optimal treatment and/or surveillance of monochorionic pregnancies diagnosed with TAPS are poorly established.**

D

Fetoscopic laser ablation for the treatment of TTTS, using the Solomon technique, significantly reduces the risk of recurrent disease and TAPS.<sup>15</sup> The optimal management of TAPS, once it occurs, is not clear from the literature, but possible options include expectant management, delivery, intrauterine blood transfusion (intravenous and/or intraperitoneal, with or without partial exchange transfusion), selective feticide or fetoscopic laser surgery.<sup>86</sup> There is little evidence relating to the outcome and optimal management of TAPS. Fetoscopic laser surgery is the only treatment for the cause of this disease (in analogy with TTTS), but is technically challenging due to the absence of polyhydramnios and the presence of only minuscule anastomoses.<sup>15</sup> If detected prenatally, management options need to be individualised and uncertainty discussed with the parents.

Evidence level 3

Perinatal outcome in TAPS is not well described (with or without treatment) and appears to vary according to the severity. Outcome may range from double intrauterine fetal demise to the birth of two healthy neonates with a significant inter-twin haemoglobin discordance. Knowledge on the neonatal and long-term morbidity in TAPS is scarce and based on case reports and small series.<sup>52,86</sup> Neonatal morbidity in TAPS appears to be mainly limited to haematological problems at birth. Donor twins may be severely anaemic and require blood transfusions, whereas recipient twins may be severely polycythaemic and require partial exchange transfusion.<sup>52</sup> There have been cases of severe cerebral injury in TAPS described.<sup>87</sup>

Evidence  
level 3

#### 7.4 *The management of monochorionic twin pregnancies complicated by single twin demise*

##### 7.4.1 **What are the consequences for the surviving twin after fetal death of the co-twin in a monochorionic pregnancy and what is optimal clinical management?**

Clinicians should be aware that monochorionic pregnancies not complicated by TTTS, sGR or TAPS are still at risk of fetal death and neurological abnormality.

D

After a single fetal death in a monochorionic pregnancy, clinicians should be aware that the risks to the surviving twin of death or neurological abnormality are of the order of 15% and 26%, respectively.

B

Single fetal death in a monochorionic pregnancy should be referred and assessed in a fetal medicine centre, with multidisciplinary expertise to manage these cases.

✓

Fetal magnetic resonance imaging (MRI) of the brain may be performed 4 weeks after co-twin demise to detect neurological morbidity if this information would be of value in planning management.

D

In monochorionic twins, where the placental vascular anastomoses remain intact, there is a risk of acute 'inter-twin' transfusional events causing fetal death and morbidity in the form of neurological morbidity. This is true of apparently uncomplicated monochorionic twins, but more prevalent in monochorionic twins complicated by sGR and even treated TTTS.<sup>1,4</sup>

Damage to the surviving monochorionic twin after the death of its co-twin is believed to be caused by acute haemodynamic changes around the time of death, with the survivor losing part of its circulating volume into the circulation of the dying twin. This may cause transient or persistent hypotension and low perfusion, leading to the risk of ischaemic organ damage, notably but not exclusively, to the watershed areas of the brain.<sup>88</sup>

Evidence  
level 3

Systematic reviews<sup>89,90</sup> have identified 22 full manuscripts considered of high enough quality of evidence to include in the review and meta-analysis. Twenty manuscripts were used to calculate overall summary statistics for monochorionic and dichorionic twins showing rates of co-twin death after single fetal death (15% compared with 3%), rates of preterm delivery after single fetal death (68% compared with 54%), the rate of abnormal postnatal cranial imaging after single fetal death (34% compared with 16%) and the rate of neurodevelopmental impairment after single fetal death (26% compared with 2%). Odds ratios were calculated from 16 manuscripts. There was no significant difference reported between preterm delivery of monochorionic and dichorionic twins (OR 1.1, 95% CI 0.34–3.51;  $P = 0.9$ ). After single fetal death, monochorionic twins had higher odds of abnormal cranial imaging after delivery, although, this was not significant (OR 3.25, 95% CI 0.66–16.1;  $P = 0.12$ ). After single fetal death, monochorionic twins were 4.81 times more likely to have neurodevelopmental morbidity (95% CI 1.39–16.6;  $P < 0.05$ ).

Evidence level 1–

Clinical management is complex and should be overseen by fetal medicine experts with the knowledge and experience to advise parents about the advantages and disadvantages of different approaches.<sup>91</sup> Rapid delivery is usually unwise, unless at term, as fetal brain injury of the surviving twin occurs at the time of demise of the co-twin. Therefore, immediate delivery only adds prematurity to the possible hypotensive cerebral injury the surviving twin may have already sustained. Serious compromise of the surviving fetus may be anticipated and this should be discussed with parents, including the significant risk of long-term morbidity. Evidence of fetal compromise (such as significant cardiotocographic abnormality and/or evidence of anaemia in the survivor if single fetal death occurs late in pregnancy) could represent continuing and/or established damage to the brain. Fetal anaemia in the surviving twin may be or have been associated with cerebral hypoperfusion and therefore, may be associated with future development of neurological morbidity.<sup>89–91</sup>

Evidence level 4

A conservative management policy is often appropriate, with serial fetal brain ultrasound imaging and a fetal cranial MRI scan planned, commonly 4 weeks after the 'sentinel event'.<sup>90,91</sup> The appearances of intracranial neurological morbidity on ultrasound are variable and may take up to 4 weeks to develop. Fetal MRI provides earlier and more detailed information about brain lesions (haemorrhagic or ischaemic) in the surviving fetus than ultrasound and its use should be considered.<sup>92,93</sup>

Evidence level 3

In cases of single intrauterine demise with MRI or ultrasound findings of neurological morbidity, late termination of pregnancy would be an option. The gestational age at the time of diagnosis is relevant and the views of the parents will be of paramount importance.

#### 7.4.2 How should fetal anaemia be monitored after single twin intrauterine death?

**Fetal anaemia may be assessed by measurement of the fetal MCA PSV using Doppler ultrasonography.**

D

In a prospective series of 20 monochorionic pregnancies complicated by single fetal death, there was a strong correlation between fetal anaemia (assessed by cordocentesis) and fetal MCA PSV.<sup>94</sup>

Evidence level 3

In a small series (n = 26) of pregnancies complicated by TTTS and single fetal death, the prognosis was worse for donor twins following the death of the recipient twin than vice versa. This is in keeping with the concept of enhanced blood loss through a unidirectional anastomosis.<sup>95</sup> There are a few reports of intrauterine transfusion of anaemic surviving co-twins, but the value of this intervention is not established within the context of preventing perinatal and long-term neurological morbidity.<sup>96,97</sup>

Evidence level 3

The presence of an increased MCA PSV in the surviving twin would suggest fetal anaemia and therefore, a significant inter-twin transfusion. This would increase the risk of hypotensive neurological injury and thus, would be helpful information in the counselling of parents and timing of fetal brain MRI. Treatment by intrauterine transfusion is controversial, as this may improve fetal survival without reducing the long-term risks of neurological morbidity.

## 8. Timing and mode of delivery in uncomplicated monochorionic pregnancies

### 8.1 *What is the optimal timing and method of delivery for otherwise uncomplicated monochorionic pregnancies (without TTTS, sGR or TAPS)?*

**Women with monochorionic twins should have timing of birth discussed and be offered elective delivery from 36<sup>+0</sup> weeks with the administration of antenatal steroids, unless there is an indication to deliver earlier.**

C

**It is appropriate to aim for vaginal birth of MCDA twins unless there are other specific clinical indications for caesarean section.**

A

For uncomplicated monochorionic pregnancies there may be a higher risk of unexplained fetal demise despite intensive fetal surveillance.<sup>98</sup> The 2011 NICE guideline examined this topic.<sup>1</sup> Gestational age profile for spontaneous birth in twin and triplet pregnancies was assessed in one cross-sectional study which suggested that the majority (58%) of women with uncomplicated twin pregnancies give birth spontaneously before 37<sup>+0</sup> weeks.<sup>21</sup>

Evidence level 2–

Furthermore, a 2013 systematic review concluded that even uncomplicated monochorionic twin pregnancies are at substantial risk of stillbirth throughout the third trimester, which is several-fold higher than in dichorionic twin pregnancies. Given the risk of fetal death to the co-twin, these data should inform decisions around timing of delivery in seemingly normal monochorionic twin pregnancies; women with monochorionic twins should be offered elective birth from 36<sup>+0</sup> weeks with the administration of antenatal steroids.<sup>1,98</sup>

Evidence level 2+

The Twin Birth Study,<sup>99</sup> a multicentre, international randomised controlled trial of planned vaginal birth versus planned caesarean section for delivery of twins, included a subcohort of uncomplicated MCDA twins (600 of 1398 randomised). The study concluded that in twin pregnancies between 32<sup>+0</sup> and 38<sup>+6</sup> weeks of gestation (when the first twin is a cephalic presentation), planned caesarean section delivery did not significantly decrease (or increase) the risks of fetal or neonatal death, or serious newborn morbidity as compared with vaginal delivery. Furthermore, post hoc subgroup analysis demonstrated no significant interaction of chorionicity with the primary outcomes. It was concluded that there was no significant benefit from planned caesarean section for any subgroup, including monochorionic twins.

Evidence level 1+

As with all pregnancies, parental views will also be important in reaching a conclusion about the best, individualised method of monochorionic twin delivery, including opting for caesarean section.

In addition to the complexities of twin delivery (i.e. malpresentation) there is a small risk of acute feto–fetal transfusional events during labour and this is one of the reasons why continuous electronic fetal monitoring during labour is recommended.

## 9. MCMA pregnancies

### 9.1 *What are the specific problems of MCMA pregnancies and how should they be managed?*

**MCMA twins almost always have umbilical cord entanglement when visualised using colour flow Doppler. Such a finding has not consistently been demonstrated to contribute to overall morbidity and mortality.**

D

**MCMA twins have a high risk of fetal death and should be delivered by caesarean section between 32<sup>+0</sup> and 34<sup>+0</sup> weeks.**

D

MCMA twins have classically been thought to be at risk from cord entanglement (almost always visualised) and fetal demise. A retrospective study of 30 MCMA twin pairs reported a total survival of 60%.<sup>7</sup> Two pairs died after 32 weeks. Of the ten twin pairs that died in utero, cord entanglement was documented in eight. The authors recommended elective delivery at 32 weeks of gestation.

Evidence level 3

However, a study of 32 MCMA twin pregnancies has suggested that cord entanglement is a feature of all MCMA twin pregnancies and most deaths occur prior to 20 weeks due to other causes (TRAP or discordant fetal anomaly).<sup>100</sup> MCMA twins are, therefore, probably not as dangerous as previously thought, although, surveillance and management should always be individualised.<sup>101</sup> Management by using sulindac to reduce amniotic fluid volumes has been advocated, but evidence for this treatment is scanty. The authors, therefore, recommended re-evaluating the very early timing of delivery for MCMA twins.<sup>100,101</sup>

Evidence level 2–

A retrospective multicentre cohort study of 193 MCMA twin sets found that fetal deaths occurred in 18.1% of fetuses. The prospective risk of a nonrespiratory neonatal complication was significantly lower than the prospective risk of fetal death after 32<sup>+4</sup> weeks. This consortium's recommendation was to deliver MCMA twins at approximately 33 weeks of gestation. All such cases should be managed in fetal medicine centres with specialist expertise and decisions on delivery made on an individual basis.<sup>102</sup>

## 10. Higher order multiple pregnancies with reference to monochorionicity

### 10.1 *What is the outcome of monochorionic and dichorionic compared with trichorionic triplet pregnancies?*

**Clinicians should be aware that monochorionic/dichorionic triplet pregnancies have higher fetal loss rates than trichorionic triplet pregnancies and may be complicated by feto–fetal transfusion syndrome, sGR and TAPS.**

C

**Selective reduction should be discussed in all higher order pregnancies including triplets.**



**Increased ultrasound surveillance is warranted in a fetal medicine centre with expertise to manage such cases.**



A retrospective study of 88 naturally conceived triplet pregnancies managed in three tertiary referral units in the UK found a 5.5-fold increased risk of perinatal death in dichorionic triamniotic pregnancies (that is, containing monochorionic twins) than trichorionic triamniotic pregnancies (OR 5.5, 95% CI 2.5–12.2).<sup>103</sup> Referral bias may have influenced the findings. A similar retrospective study from two tertiary centres in Germany described 84% survival in fetuses of monochorionic and dichorionic triplet pregnancies combined compared with 92% in fetuses of trichorionic triplet pregnancies.<sup>104</sup> This difference did not reach statistical significance.

Evidence level 3

The consensus views arising from the 50th RCOG Study Group<sup>4</sup> recommend that selective reduction should be discussed in all higher order pregnancies. A systematic review provides information on the risks of this procedure in trichorionic triplets and on the alternative option of conservative management (from six cohort studies).<sup>105</sup> In the reduction group ( $n = 482$  pregnancies) compared with the expectantly managed group ( $n = 411$ ), the rate of miscarriage (before 24 weeks) was higher (8.1% versus 4.4%; relative risk [RR] 1.83, 95% CI 1.08–3.16;  $P = 0.036$ ) and the rate of early preterm delivery was lower (10.4% versus 26.7%; RR 0.37, 95% CI 0.27–0.51;  $P < 0.0001$ ). It was calculated that seven (95% CI 5–9) reductions needed to be performed to prevent one early preterm delivery, while the number of reductions that would cause one miscarriage was 26 (95% CI 14–193).<sup>105</sup>

Evidence level 2+

In monochorionic or dichorionic triamniotic triplets (because of shared placental vasculature), this would mean either a procedure to reduce the fetal numbers to one or to consider intrafetal ablative therapy to reduce dichorionic triplets to dichorionic twins.<sup>106</sup> Such options are associated with an increase in total pregnancy loss.

Evidence level 3

If TTTS does occur, then it is most appropriately treated by laser ablation and the overall prognosis is better for dichorionic versus monochorionic triamniotic triplet pregnancies.<sup>76</sup>

## 11. Discordant abnormalities in monochorionic pregnancies

### 11.1 *What is the incidence of and the therapeutic options for discordant abnormalities in monochorionic pregnancies, including TRAP sequence?*

**Monochorionic twins that are discordant for fetal anomaly must be referred promptly for assessment and counselling in a fetal medicine centre with consideration for treatment.**



**Karyotyping of monochorionic twins should be managed in a fetal medicine centre.**



**Meticulous mapping of the position of the twins within the uterus should be performed both at the time of prenatal diagnostic tests and invasive treatments.**





During amniocentesis, both amniotic sacs should be sampled in monochorionic twin pregnancies, unless monochorionicity is confirmed before 14 weeks and the fetuses appear concordant for growth and anatomy.



Prior to invasive testing or in the context of twins discordant for an abnormality, selective reduction should be discussed and made available to those requesting the procedure after appropriate counselling.



Monitoring for disseminated intravascular coagulopathy is not indicated in monochorionic twin pregnancies undergoing selective reduction.



Selective feticide by intravascular injection of an abortifacient is not an option in monochorionic pregnancies because of the presence of placental anastomoses. The potential risks of intrafetal/umbilical cord ablative procedures should be discussed prospectively, including the risk of co-twin loss and neurological morbidity.



Documentation and discussion of heterokaryotypic monozygotic karyotypic abnormalities should take place.



A higher rate of structural anomalies is observed in twins compared with singletons.<sup>26,39</sup> Approximately 1–2% of twin pregnancies face the dilemma of expectant management versus selective termination following diagnosis of an anomaly affecting only one fetus.

In a structurally or size discordant monochorionic pair, discordant aneuploidy is exceedingly rare, although, not impossible. Structural anomalies in monochorionic pregnancies are twice that expected in dichorionic pairs, given the monozygosity.<sup>39</sup> Detailed ultrasound assessment, fetal karyotyping and a discussion of prognosis is required with reference both to the abnormal and normal twin.

Selective termination in a monochorionic pregnancy is an option,<sup>78,79</sup> but as the fetal circulations are not independent, it cannot be performed with injection of medical therapeutics because of the effect on the co-twin. More invasive and higher risk procedures, such as cord coagulation, and intrafetal ablative procedures, such as radiofrequency ablation, are necessary to induce termination of one twin without causing morbidity or death in its co-twin.<sup>79</sup>

Evidence level 4

It is essential that at the time of prenatal diagnostic tests, the pregnancy is mapped carefully, noting the position and site of the fetuses in relation to the placenta and amniotic sac, and documented. This is ideally performed by the operator who would perform the technique of selective termination of pregnancy if required. It is mandatory to discuss selective termination of pregnancy and complicating factors in monochorionic twins, including the potential risk to the normal twin.<sup>1,34</sup>

Twin and triplet pregnancies in which the abnormal fetus underwent umbilical cord coagulation by bipolar diathermy or intrafetal laser ablation for indications that included severe discordant abnormalities or TRAP sequence have been described.<sup>107,108</sup> Overall, up to 82% of co-twins survived. Preterm rupture of membranes (10–15%) and chorioamnionitis remain significant complications. Fetal loss rates are 15–18% and some series have recorded transfusional neurological sequelae in up to 15%. Similar experience is reported using radiofrequency ablation.<sup>83,109</sup>

Monochorionic twins complicated with an acardiac twin and TRAP sequence do not always require invasive treatment. Selection for treatment appears to be dependent on:

- the relative size of the 'acardiac' twin to the 'pump' twin (the larger the acardiac twin, the greater the risk and need for therapy) and
- the presence of any cardiovascular impairment in the 'pump' twin.<sup>110</sup>

If treatment is considered, then there is some evidence that treatment should take place before 16 weeks of gestation (but evidence is not strong) and it should be performed in centres with expertise in such treatment modalities. Careful monitoring and ultrasound surveillance are required.<sup>83</sup>

Rarely, monozygous twins can have different chromosome make-ups. This is known as heterokaryotypic monozygous twinning. When anomalies are identified in the first or early second trimester in one of a monochorionic twin pair which may be markers of aneuploidy, a discussion should take place as to the merits and risks of chorionic villus sampling versus waiting for a double amniocentesis at 15–16 weeks when both sacs are sampled and the individual karyotype of each twin can be determined with certainty.<sup>34</sup>

Evidence level 3

Evidence level 4

## 12. Conjoined twins

### 12.1 *How are conjoined twins diagnosed and what are the outcomes?*

**Conjoined twins are exceedingly rare and prenatal assessment is required in a tertiary fetal medicine centre so that diagnosis can be confirmed and prognosis discussed in conjunction with a multidisciplinary team.**





Conjoined twins are very rare and by definition are MCMA twin pregnancies. The prevalence is one in 90 000 to 100 000 pregnancies. The underlying pathogenic mechanism remains uncertain. Such MCMA twins are complex and require careful detailed expert ultrasound imaging (usually including MRI) and multidisciplinary discussion. In one series of 14 cases of prenatally diagnosed conjoined twins at a single referral centre, 20% of parents opted for termination of pregnancy, 10% of fetuses died in utero and the overall individual survival rate to discharge of those attempting pregnancy continuation was about 25%, the majority of whom have significant morbidity.<sup>111</sup> Most cases are now prenatally diagnosed and delivered by elective caesarean section, but vaginal deliveries of conjoined twins are reported.<sup>112</sup> Risk of dystocia and uterine rupture has been reported in association with cases undiagnosed prenatally.


Evidence level 2–

Prenatal diagnosis of conjoined twins with ultrasound is now well reported from the first trimester, with detailed assessment of cardiovascular anatomy important for determining prognosis and planning management.

### 13. What are the training competencies required for managing monochorionic pregnancies?

All sonographers who undertake routine ultrasound scans during pregnancy must be trained to establish chorionicity and the correct labelling of twins. 

All sonographers who undertake midtrimester (18<sup>+0</sup>–20<sup>+6</sup> weeks) and fetal growth scans of monochorionic twins should be made aware of the appearances of TTTS, sGR and TAPS, and the need to refer patients on to specialist centres if such features present. 

Fetal medicine centres undertaking fetal therapy for relatively rare complications of monochorionic twins should have a minimum of two experienced operators and more than 15 cases per year (rolling 3-year average) to maximise perinatal outcomes and minimise long-term morbidity. 

Fetal medicine centres should follow the NHS England Specialised Services Clinical Reference Group for Fetal Medicine recommendations for experience.<sup>68</sup>

Evidence level 4

### 14. Recommendations for future research

- The use of serial MCA PSV in screening for TAPS in women with monochorionic twins and its evaluation in a diagnostic accuracy study, with relevance to pregnancy outcomes.
- Research evaluating early versus late treatment for monochorionic twins complicated by TRAP sequence and its assessment in terms of pregnancy outcomes.

### 15. Auditable topics

- Prospective outcome (primary outcomes: perinatal mortality and long-term paediatric morbidity) after fetoscopic laser ablation for TTTS corrected for stage, experience of operators and severity of disease at presentation. At least one survivor in 85% of twins.
- Offer women who present in the first trimester with monochorionic twins screening for trisomy 21 (100%).
- The proportion of neurological morbidity post laser ablation for the treatment of TTTS in each fetus (less than 10%).
- Labelling of twins undertaken at first scan and followed consistently with serial scans (100%).
- The proportion of monochorionic twins who have extended fetal heart views undertaken at the midtrimester anomaly scan (more than 85%).
- The proportion of monochorionic twins who have 2-weekly ultrasound from 16 weeks of gestation (more than 95%).

### 16. Useful links and support groups

- National Institute for Health and Clinical Excellence. *Multiple pregnancy. The management of twin and triplet pregnancies in the antenatal period*. NICE clinical guideline 129. Manchester: NICE; 2011 [<https://www.nice.org.uk/guidance/cg129>].
- Royal College of Obstetricians and Gynaecologists. *Multiple pregnancy: having more than one baby. Information for you*. London: RCOG; 2016 [<https://www.rcog.org.uk/en/patients/patient-leaflets/multiple-pregnancy-having-more-than-one-baby/>].
- The Multiple Births Foundation [<http://www.multiplebirths.org.uk/>].
- Twins And Multiple Births Association [<https://www.tamba.org.uk/>].

## References

- National Institute for Health and Clinical Excellence. *Multiple pregnancy. The management of twin and triplet pregnancies in the antenatal period*. NICE clinical guideline 129. Manchester: NICE; 2011.
- Nakasuji T, Saito H, Araki R, Nakaza A, Nakashima A, Kuwahara A, et al. The incidence of monozygotic twinning in assisted reproductive technology: analysis based on results from the 2010 Japanese ART national registry. *J Assist Reprod Genet* 2014;31:803–7.
- Kawachiya S, Bodri D, Shimada N, Kato K, Takehara Y, Kato O. Blastocyst culture is associated with an elevated incidence of monozygotic twinning after single embryo transfer. *Fertil Steril* 2011;95:2140–2.
- Kilby MD, Baker PN, Critchley HO, Field DJ, editors. Consensus views arising from the 50th Study Group: Multiple Pregnancy. In: *Multiple Pregnancy*. London: RCOG Press; 2006. p. 283–6.
- Visintin C, Muggleston MA, James D, Kilby MD; Guideline Development Group. Antenatal care for twin and triplet pregnancies: summary of NICE guidance. *BMJ* 2011;343:d5714.
- NHS Evidence. *Multiple pregnancy: Evidence Update March 2013. A summary of selected new evidence relevant to NICE clinical guideline 129 'The management of twin and triplet pregnancies in the antenatal period' (2011)*. Evidence Update 37. Manchester: NICE; 2013.
- Ezra Y, Shveiky D, Ophir E, Nadjari M, Eisenberg VH, Samueloff A, et al. Intensive management and early delivery reduce antenatal mortality in monoamniotic twin pregnancies. *Acta Obstet Gynecol Scand* 2005;84:432–5.
- Denbow ML, Cox P, Taylor M, Hammal DM, Fisk NM. Placental angioarchitecture in monochorionic twin pregnancies: relationship to fetal growth, fetofetal transfusion syndrome, and pregnancy outcome. *Am J Obstet Gynecol* 2000;182:417–26.
- de Villiers SF, Slaghekke F, Middeldorp JM, Walther FJ, Oepkes D, Lopriore E. Arterio-arterial vascular anastomoses in monochorionic placentas with and without twin–twin transfusion syndrome. *Placenta* 2012;33:652–4.
- Kilby MD, Platt C, Whittle MJ, Oxley J, Lindop GB. Renin gene expression in fetal kidneys of pregnancies complicated by twin–twin transfusion syndrome. *Pediatr Dev Pathol* 2001;4:175–9.
- Umur A, van Gemert MJ, Nikkels PG. Monoamniotic-versus diamniotic-monochorionic twin placentas: anastomoses and twin–twin transfusion syndrome. *Am J Obstet Gynecol* 2003;189:1325–9.
- Zhao DP, de Villiers SF, Slaghekke F, Walther FJ, Middeldorp JM, Oepkes D, et al. Prevalence, size, number and localization of vascular anastomoses in monochorionic placentas. *Placenta* 2013;34:589–93.
- Chang YL, Chang SD, Chao AS, Hsieh PC, Wang CN, Wang TH. Clinical outcome and placental territory ratio of monochorionic twin pregnancies and selective intrauterine growth restriction with different types of umbilical artery Doppler. *Prenat Diagn* 2009;29:253–6.
- Gallot D, Saulnier JP, Savary D, Laurichesse-Delmas H, Lemery D. Ultrasonographic signs of twin–twin transfusion syndrome in a monoamniotic twin pregnancy. *Ultrasound Obstet Gynecol* 2005;25:308–9.
- Slaghekke F, Lopriore E, Lewi L, Middeldorp JM, van Zwet EW, Weingertner AS, et al. Fetoscopic laser coagulation of the vascular equator versus selective coagulation for twin-to-twin transfusion syndrome: an open-label randomised controlled trial. *Lancet* 2014;383:2144–51.
- Lopriore E, Deprest J, Slaghekke F, Oepkes D, Middeldorp JM, Vandenbussche FP, et al. Placental characteristics in monochorionic twins with and without twin anemia-polycythemia sequence. *Obstet Gynecol* 2008;112:753–8.
- Lopriore E, Slaghekke F, Oepkes D, Middeldorp JM, Vandenbussche FP, Walther FJ. Hematological characteristics in neonates with twin anemia–polycythemia sequence (TAPS). *Prenat Diagn* 2010;30:251–5.
- Slaghekke F, Kist WJ, Oepkes D, Pasma SA, Middeldorp JM, Klumper FJ, et al. Twin anemia-polycythemia sequence: diagnostic criteria, classification, perinatal management and outcome. *Fetal Diagn Ther* 2010;27:181–90.
- Lewi L, Deprest J. Management of twin pregnancies: where do we go from here? *Ultrasound Obstet Gynecol* 2013;41:601–4.
- Sebire NJ, D'Ercole C, Soares W, Nayar R, Nicolaides KH. Intertwin disparity in fetal size in monochorionic and dichorionic pregnancies. *Obstet Gynecol* 1998;91:82–5.
- National Collaborating Centre for Women's and Children's Health. *Multiple pregnancy: The management of twin and triplet pregnancies in the antenatal period*. NICE Clinical Guideline. London: RCOG Press; 2011.
- Lopriore E, Sueters M, Middeldorp JM, Klumper F, Oepkes D, Vandenbussche FP. Twin pregnancies with two separate placental masses can still be monochorionic and have vascular anastomoses. *Am J Obstet Gynecol* 2006;194:804–8.
- Senat MV, Quarello E, Levailant JM, Buonumano A, Bouvain M, Frydman R. Determining chorionicity in twin gestations: three-dimensional (3D) multiplanar sonographic measurement of intra-amniotic membrane thickness. *Ultrasound Obstet Gynecol* 2006;28:665–9.
- Carroll SG, Soothill PW, Abdel-Fattah SA, Porter H, Montague I, Kyle PM. Prediction of chorionicity in twin pregnancies at 10–14 weeks of gestation. *BJOG* 2002;109:182–6.
- D'Alton ME, Dudley DK. The ultrasonographic prediction of chorionicity in twin gestation. *Am J Obstet Gynecol* 1989;160:557–61.
- Sperling L, Kiil C, Larsen LU, Brocks V, Wojdemann KR, Qvist I, et al. Detection of chromosomal abnormalities, congenital abnormalities and transfusion syndrome in twins. *Ultrasound Obstet Gynecol* 2007;29:517–26.
- Hack KE, Derks JB, Elias SG, Franx A, Roos EJ, Voerman SK, et al. Increased perinatal mortality and morbidity in monochorionic versus dichorionic twin pregnancies: clinical implications of a large Dutch cohort study. *BJOG* 2008;115:58–67.
- Southwest Thames Obstetric Research Collaborative (STORK). Prospective risk of late stillbirth in monochorionic twins: a regional cohort study. *Ultrasound Obstet Gynecol* 2012;39:500–4.
- D'Antonio F, Khalil A, Dias T, Thilaganathan B; Southwest Thames Obstetric Research Collaborative (STORK). Crown–rump length discordance and adverse perinatal outcome in twins: analysis of the Southwest Thames Obstetric Research Collaborative (STORK) multiple pregnancy cohort. *Ultrasound Obstet Gynecol* 2013;41:621–6.
- Sebire NJ, Snijders RJ, Hughes K, Sepulveda W, Nicolaides KH. The hidden mortality of monochorionic twin pregnancies. *Br J Obstet Gynaecol* 1997;104:1203–7.

31. Lewi L, Jani J, Blickstein I, Huber A, Gucciardo L, Van Mieghem T, et al. The outcome of monochorionic diamniotic twin gestations in the era of invasive fetal therapy: a prospective cohort study. *Am J Obstet Gynecol* 2008;199:514.e1–8.
32. Barigye O, Pasquini L, Galea P, Chambers H, Chappell L, Fisk NM. High risk of unexpected late fetal death in monochorionic twins despite intensive ultrasound surveillance: a cohort study. *PLoS Med* 2005;2:e172.
33. Adegbite AL, Castille S, Ward S, Bajoria R. Neuromorbidity in preterm twins in relation to chorionicity and discordant birth weight. *Am J Obstet Gynecol* 2004;190:156–63.
34. Audibert F, Gagnon A; Genetics Committee of the Society of Obstetricians and Gynaecologists of Canada; Prenatal Diagnosis Committee of the Canadian College of Medical Geneticists. Prenatal screening for and diagnosis of aneuploidy in twin pregnancies. *J Obstet Gynaecol Can* 2011;33:754–67.
35. Garchet-Beaudron A, Dreux S, Leporrier N, Oury JF, Muller F; ABA Study Group; Clinical Study Group. Second-trimester Down syndrome maternal serum marker screening: a prospective study of 11 040 twin pregnancies. *Prenat Diagn* 2008;28:1105–9.
36. Gil MM, Akolekar R, Quezada MS, Bregant B, Nicolaides KH. Analysis of cell-free DNA in maternal blood in screening for aneuploidies: meta-analysis. *Fetal Diagn Ther* 2014;35:156–73.
37. Huang X, Zheng J, Chen M, Zhao Y, Zhang C, Liu L, et al. Noninvasive prenatal testing of trisomies 21 and 18 by massively parallel sequencing of maternal plasma DNA in twin pregnancies. *Prenat Diagn* 2014;34:335–40.
38. Bevilacqua E, Gil MM, Nicolaides KH, Ordoñez E, Cirigliano V, Dierickx H, et al. Performance of screening for aneuploidies by cell-free DNA analysis of maternal blood in twin pregnancies. *Ultrasound Obstet Gynecol* 2015;45:61–6.
39. Hall JG. Twinning. *Lancet* 2003;362:735–43.
40. Chang YL, Chao AS, Cheng PJ, Chung CL, Chueh HY, Chang SD, et al. Presence of a single fetal major anomaly in a twin pregnancy does not increase the preterm rate. *Aust N Z J Obstet Gynaecol* 2004;44:332–6.
41. Li H, Meng T, Shang T, Guan YP, Zhou WW, Yang G, et al. Fetal echocardiographic screening in twins for congenital heart diseases. *Chin Med J (Engl)* 2007;120:1391–4.
42. Anderson BL, Sherman FS, Mancini F, Simhan HN. Fetal echocardiographic findings are not predictive of death in twin-twin transfusion syndrome. *J Ultrasound Med* 2006;25:455–9.
43. NHS fetal anomaly screening programme (FASP). [www.gov.uk/topic/population-screening-programmes/fetal-anomaly]. Accessed 2015 Nov 5.
44. Lewi L, Lewi P, Diemert A, Jani J, Gucciardo L, Van Mieghem T, et al. The role of ultrasound examination in the first trimester and at 16 weeks' gestation to predict fetal complications in monochorionic diamniotic twin pregnancies. *Am J Obstet Gynecol* 2008;199:493.e1–7.
45. Giles WB. Doppler ultrasound in multiple pregnancies. *Baillieres Clin Obstet Gynaecol* 1998;12:77–89.
46. Stirrup OT, Khalil A, D'Antonio F, Thilaganathan B; Southwest Thames Obstetric Research Collaborative (STORK). Fetal growth reference ranges in twin pregnancy: analysis of the Southwest Thames Obstetric Research Collaborative (STORK) multiple pregnancy cohort. *Ultrasound Obstet Gynecol* 2015;45:301–7.
47. Khalil A, D'Antonio F, Dias T, Cooper D, Thilaganathan B; Southwest Thames Obstetric Research Collaborative (STORK). Ultrasound estimation of birth weight in twin pregnancy: comparison of biometry algorithms in the STORK multiple pregnancy cohort. *Ultrasound Obstet Gynecol* 2014;44:210–20.
48. Van Mieghem T, Eixarch E, Gucciardo L, Done E, Gonzales I, Van Schoubroeck D, et al. Outcome prediction in monochorionic diamniotic twin pregnancies with moderately discordant amniotic fluid. *Ultrasound Obstet Gynecol* 2011;37:15–21.
49. Quintero RA, Morales WJ, Allen MH, Bornick PW, Johnson PK, Kruger M. Staging of twin-twin transfusion syndrome. *J Perinatol* 1999;19:550–5.
50. Quintero RA, Dickinson JE, Morales WJ, Bornick PW, Bermúdez C, Cincotta R, et al. Stage-based treatment of twin-twin transfusion syndrome. *Am J Obstet Gynecol* 2003;188:1333–40.
51. Robyr R, Lewi L, Salomon LJ, Yamamoto M, Bernard JP, Deprest J, et al. Prevalence and management of late fetal complications following successful selective laser coagulation of chorionic plate anastomoses in twin-to-twin transfusion syndrome. *Am J Obstet Gynecol* 2006;194:796–803.
52. Lopriore E, Slaghekke F, Oepkes D, Middeldorp JM, Vandenbussche FP, Walther FJ. Clinical outcome in neonates with twin anemia-polycythemia sequence. *Am J Obstet Gynecol* 2010;203:54.e1–5.
53. Valsky DV, Eixarch E, Martinez JM, Crispi F, Gratacós E. Selective intrauterine growth restriction in monochorionic twins: pathophysiology, diagnostic approach and management dilemmas. *Semin Fetal Neonatal Med* 2010;15:342–8.
54. D'Antonio F, Khalil A, Dias T, Thilaganathan B; Southwest Thames Obstetric Research Collaborative (STORK). Weight discordance and perinatal mortality in twins: analysis of the Southwest Thames Obstetric Research Collaborative (STORK) multiple pregnancy cohort. *Ultrasound Obstet Gynecol* 2013;41:643–8.
55. Harper LM, Roehl KA, Tuuli MG, Odibo AO, Cahill AG. Sonographic accuracy of estimated fetal weight in twins. *J Ultrasound Med* 2013;32:625–30.
56. Breathnach FM, McAuliffe FM, Geary M, Daly S, Higgins JR, Dornan J, et al; Perinatal Ireland Research Consortium. Definition of intertwin birth weight discordance. *Obstet Gynecol* 2011;118:94–103.
57. Gratacós E, Lewi L, Muñoz B, Acosta-Rojas R, Hernandez-Andrade E, Martinez JM, et al. A classification system for selective intrauterine growth restriction in monochorionic pregnancies according to umbilical artery Doppler flow in the smaller twin. *Ultrasound Obstet Gynecol* 2007;30:28–34.
58. D'Antonio F, Khalil A, Thilaganathan B; Southwest Thames Obstetric Research Collaborative (STORK). Second-trimester discordance and adverse perinatal outcome in twins: the STORK multiple pregnancy cohort. *BJOG* 2014;121:422–9.
59. Gratacós E, Lewi L, Carreras E, Becker J, Higuera T, Deprest J, et al. Incidence and characteristics of umbilical artery intermittent absent and/or reversed end-diastolic flow in complicated and uncomplicated monochorionic twin pregnancies. *Ultrasound Obstet Gynecol* 2004;23:456–60.
60. Dickinson JE, Evans SF. The progression of disease stage in twin-twin transfusion syndrome. *J Matern Fetal Neonatal Med* 2004;16:95–101.
61. Luks FI, Carr SR, Plevyak M, Craigo SD, Athanassiou A, Ralston SJ, et al. Limited prognostic value of a staging system for twin-to-twin transfusion syndrome. *Fetal Diagn Ther* 2004;19:301–4.
62. Taylor MJ, Govender L, Jolly M, Wee L, Fisk NM. Validation of the Quintero staging system for twin-twin transfusion syndrome. *Obstet Gynecol* 2002;100:1257–65.
63. Huber A, Diehl W, Bregenzer T, Hackelöer BJ, Hecher K. Stage-related outcome in twin-twin transfusion syndrome treated by fetoscopic laser coagulation. *Obstet Gynecol* 2006;108:333–7.


64. Michelfelder E, Gottliebson W, Border W, Kinsel M, Polzin W, Livingston J, et al. Early manifestations and spectrum of recipient twin cardiomyopathy in twin-twin transfusion syndrome: relation to Quintero stage. *Ultrasound Obstet Gynecol* 2007;30:965–71.
65. Raboisson MJ, Fouron JC, Lamoureux J, Leduc L, Grignon A, Proulx F, et al. Early intertwin differences in myocardial performance during the twin-to-twin transfusion syndrome. *Circulation* 2004;110:3043–8.
66. Huber A, Diehl W, Zikulnig L, Bregenzer T, Hackelöer BJ, Hecher K. Perinatal outcome in monochorionic twin pregnancies complicated by amniotic fluid discordance without severe twin-twin transfusion syndrome. *Ultrasound Obstet Gynecol* 2006;27:48–52.
67. Ville Y. Twin-to-twin transfusion syndrome: time to forget the Quintero staging system? *Ultrasound Obstet Gynecol* 2007;30:924–7.
68. NHS England Specialised Services Clinical Reference Group for Fetal Medicine. *Clinical Commissioning Policy: Management of Twin to Twin Syndrome by fetoscopic laser ablation*. NHS England E12/P/b. London: NHS England; 2015. [https://www.england.nhs.uk/commissioning/wp-content/uploads/sites/12/2015/01/e12-mgmt-twin-twin.pdf]. Accessed 2015 Nov 5.
69. Senat MV, Deprest J, Boulvain M, Paupe A, Winer N, Ville Y. Endoscopic laser surgery versus serial amnioreduction for severe twin-to-twin transfusion syndrome. *N Engl J Med* 2004;351:136–44.
70. Moise KJ Jr, Dorman K, Lamvu G, Saade GR, Fisk NM, Dickinson JE, et al. A randomized trial of amnioreduction versus septostomy in the treatment of twin-twin transfusion syndrome. *Am J Obstet Gynecol* 2005;193:701–7.
71. Crombleholme TM, Shera D, Lee H, Johnson M, D'Alton M, Porter F, et al. A prospective, randomized, multicenter trial of amnioreduction vs selective fetoscopic laser photocoagulation for the treatment of severe twin-twin transfusion syndrome. *Am J Obstet Gynecol* 2007;197:396.e1–9.
72. Roberts D, Neilson JP, Kilby MD, Gates S. Interventions for the treatment of twin-twin transfusion syndrome. *Cochrane Database Syst Rev* 2014;(1):CD002073.
73. Baud D, Windrim R, Keunen J, Kelly EN, Shah P, van Mieghem T, et al. Fetoscopic laser therapy for twin-twin transfusion syndrome before 17 and after 26 weeks' gestation. *Am J Obstet Gynecol* 2013;208:197.e1–7.
74. Middeldorp JM, Lopriore E, Sueters M, Klumper FJ, Kanhai HH, Vandenbussche FP, et al. Twin-to-twin transfusion syndrome after 26 weeks of gestation: is there a role for fetoscopic laser surgery? *BJOG* 2007;114:694–8.
75. Van Schoubroeck D, Lewi L, Ryan G, Carreras E, Jani J, Higuera T, et al. Fetoscopic surgery in triplet pregnancies: a multicenter case series. *Am J Obstet Gynecol* 2004;191:1529–32.
76. Sepulveda W, Surerus E, Vandecruys H, Nicolaides KH. Fetofetal transfusion syndrome in triplet pregnancies: outcome after endoscopic laser surgery. *Am J Obstet Gynecol* 2005;192:161–4.
77. Taylor MJ, Shalev E, Tanawattanacharoen S, Jolly M, Kumar S, Weiner E, et al. Ultrasound-guided umbilical cord occlusion using bipolar diathermy for Stage III/IV twin-twin transfusion syndrome. *Prenat Diagn* 2002;22:70–6.
78. Paramasivam G, Wimalasundera R, Wiechec M, Zhang E, Saeed F, Kumar S. Radiofrequency ablation for selective reduction in complex monochorionic pregnancies. *BJOG* 2010;117:1294–8.
79. Wimalasundera RC. Selective reduction and termination of multiple pregnancies. *Semin Fetal Neonatal Med* 2010;15:327–35.
80. Cavicchioni O, Yamamoto M, Robyr R, Takahashi Y, Ville Y. Intrauterine fetal demise following laser treatment in twin-to-twin transfusion syndrome. *BJOG* 2006;113:590–4.
81. Blickstein I, Arabin B, Chervenak FA, Kavak ZN, Keith LG, Shinwell ES, et al. The Istanbul international consensus statement on the perinatal care of multiple pregnancy. *J Perinat Med* 2007;35:465–7.
82. Royal College of Obstetricians and Gynaecologists. *Antenatal Corticosteroids to Reduce Neonatal Morbidity and Mortality*. Green-top Guideline No. 7. London: RCOG; 2010.
83. Kumar S, Paramasivam G, Zhang E, Jones B, Noori M, Prior T, et al. Perinatal- and procedure-related outcomes following radiofrequency ablation in monochorionic pregnancy. *Am J Obstet Gynecol* 2014;210:454.e1–6.
84. Gratacós E, Carreras E, Becker J, Lewi L, Enríquez G, Perapoch J, et al. Prevalence of neurological damage in monochorionic twins with selective intrauterine growth restriction and intermittent absent or reversed end-diastolic umbilical artery flow. *Ultrasound Obstet Gynecol* 2004;24:159–63.
85. Royal College of Obstetricians and Gynaecologists. *The Investigation and Management of the Small-for-Gestational-Age Fetus*. Green-top Guideline No. 31. London: RCOG; 2013.
86. Genova L, Slaghekke F, Klumper FJ, Middeldorp JM, Steggerda SJ, Oepkes D, et al. Management of twin anemia-polycythemia sequence using intrauterine blood transfusion for the donor and partial exchange transfusion for the recipient. *Fetal Diagn Ther* 2013;34:121–6.
87. Lopriore E, Slaghekke F, Kersbergen KJ, de Vries LS, Drogtróp AP, Middeldorp JM, et al. Severe cerebral injury in a recipient with twin anemia-polycythemia sequence. *Ultrasound Obstet Gynecol* 2013;41:702–6.
88. Simões T, Amaral N, Lerman R, Ribeiro F, Dias E, Blickstein I. Prospective risk of intrauterine death of monochorionic-diamniotic twins. *Am J Obstet Gynecol* 2006;195:134–9.
89. Ong SS, Zamora J, Khan KS, Kilby MD. Prognosis for the co-twin following single-twin death: a systematic review. *BJOG* 2006;113:992–8.
90. Hillman SC, Morris RK, Kilby MD. Co-twin prognosis after single fetal death: a systematic review and meta-analysis. *Obstet Gynecol* 2011;118:928–40.
91. Shek NW, Hillman SC, Kilby MD. Single-twin demise: pregnancy outcome. *Best Pract Res Clin Obstet Gynaecol* 2014;28:249–63.
92. Righini A, Salmons S, Bianchini E, Zirpoli S, Moschetta M, Kustermann A, et al. Prenatal magnetic resonance imaging evaluation of ischemic brain lesions in the survivors of monochorionic twin pregnancies: report of 3 cases. *J Comput Assist Tomogr* 2004;28:87–92.
93. Weisz B, Hoffmann C, Ben-Baruch S, Yinon Y, Gindes L, Katorza E, et al. Early detection by diffusion-weighted sequence magnetic resonance imaging of severe brain lesions after fetoscopic laser coagulation for twin-twin transfusion syndrome. *Ultrasound Obstet Gynecol* 2014;44:44–9.
94. Senat MV, Loizeau S, Couderc S, Bernard JP, Ville Y. The value of middle cerebral artery peak systolic velocity in the diagnosis of fetal anemia after intrauterine death of one monochorionic twin. *Am J Obstet Gynecol* 2003;189:1320–4.
95. Nicolini U, Pisoni MP, Cela E, Roberts A. Fetal blood sampling immediately before and within 24 hours of death in monochorionic twin pregnancies complicated by single intrauterine death. *Am J Obstet Gynecol* 1998;179:800–3.
96. Senat MV, Bernard JP, Loizeau S, Ville Y. Management of single fetal death in twin-to-twin transfusion syndrome: a role for fetal blood sampling. *Ultrasound Obstet Gynecol* 2002;20:360–3.
97. Nakata M, Sumie M, Murata S, Miwa I, Kusaka E, Sugino N. A case of monochorionic twin pregnancy complicated with

- intrauterine single fetal death with successful treatment of intrauterine blood transfusion in the surviving fetus. *Fetal Diagn Ther* 2007;22:7–9.
98. Danon D, Sekar R, Hack KE, Fisk NM. Increased stillbirth in uncomplicated monochorionic twin pregnancies: a systematic review and meta-analysis. *Obstet Gynecol* 2013;121:1318–26.
  99. Barrett JF, Hannah ME, Hutton EK, Willan AR, Allen AC, Armson BA, et al.; Twin Birth Study Corroborative Group. A randomized trial of planned cesarean or vaginal delivery for twin pregnancy. *N Engl J Med* 2013;369:1295–305.
  100. Dias T, Mahsud-Dornan S, Bhide A, Papageorghiou AT, Thilaganathan B. Cord entanglement and perinatal outcome in monoamniotic twin pregnancies. *Ultrasound Obstet Gynecol* 2010;35:201–4.
  101. Hack KE, Derks JB, Schaap AH, Lopriore E, Elias SG, Arabin B, et al. Perinatal outcome of monoamniotic twin pregnancies. *Obstet Gynecol* 2009;113:353–60.
  102. Van Mieghem T, De Heus R, Lewi L, Klaritsch P, Kollmann M, Baud D, et al. Prenatal management of monoamniotic twin pregnancies. *Obstet Gynecol* 2014;124:498–506.
  103. Adegbite AL, Ward SB, Bajoria R. Perinatal outcome of spontaneously conceived triplet pregnancies in relation to chorionicity. *Am J Obstet Gynecol* 2005;193:1463–71.
  104. Geipel A, Berg C, Katalinic A, Plath H, Hansmann M, Germer U, et al. Prenatal diagnosis and obstetric outcomes in triplet pregnancies in relation to chorionicity. *BJOG* 2005;112:554–8.
  105. Papageorghiou AT, Avgidou K, Bakoulas V, Sebire NJ, Nicolaides KH. Risks of miscarriage and early preterm birth in trichorionic triplet pregnancies with embryo reduction versus expectant management: new data and systematic review. *Hum Reprod* 2006;21:1912–7.
  106. Chaveeva P, Kosinski P, Birdir C, Orosz L, Nicolaides KH. Embryo reduction in dichorionic triplets to dichorionic twins by intrafetal laser. *Fetal Diagn Ther* 2014;35:83–6.
  107. Lewi L, Gratacos E, Ortibus E, Van Schoubroeck D, Carreras E, Higuera T, et al. Pregnancy and infant outcome of 80 consecutive cord coagulations in complicated monochorionic multiple pregnancies. *Am J Obstet Gynecol* 2006;194:782–9.
  108. Pagani G, D'Antonio F, Khalil A, Papageorghiou A, Bhide A, Thilaganathan B. Intrafetal laser treatment for twin reversed arterial perfusion sequence: cohort study and meta-analysis. *Ultrasound Obstet Gynecol* 2013;42:6–14.
  109. Roman A, Papanna R, Johnson A, Hassan SS, Moldenhauer J, Molina S, et al. Selective reduction in complicated monochorionic pregnancies: radiofrequency ablation vs. bipolar cord coagulation. *Ultrasound Obstet Gynecol* 2010;36:37–41.
  110. Weisz B, Peltz R, Chayen B, Oren M, Zalel Y, Achiron R, et al. Tailored management of twin reversed arterial perfusion (TRAP) sequence. *Ultrasound Obstet Gynecol* 2004;23:451–5.
  111. Mackenzie TC, Crombleholme TM, Johnson MP, Schnauer L, Flake AW, Hedrick HL, et al. The natural history of prenatally diagnosed conjoined twins. *J Pediatr Surg* 2002;37:303–9.
  112. Agarwal U, Dahiya P, Khosla A. Vaginal birth of conjoined thoracopagus – a rare event. *Arch Gynecol Obstet* 2003;269:66–7.

## Appendix I: Explanation of guidelines and evidence levels

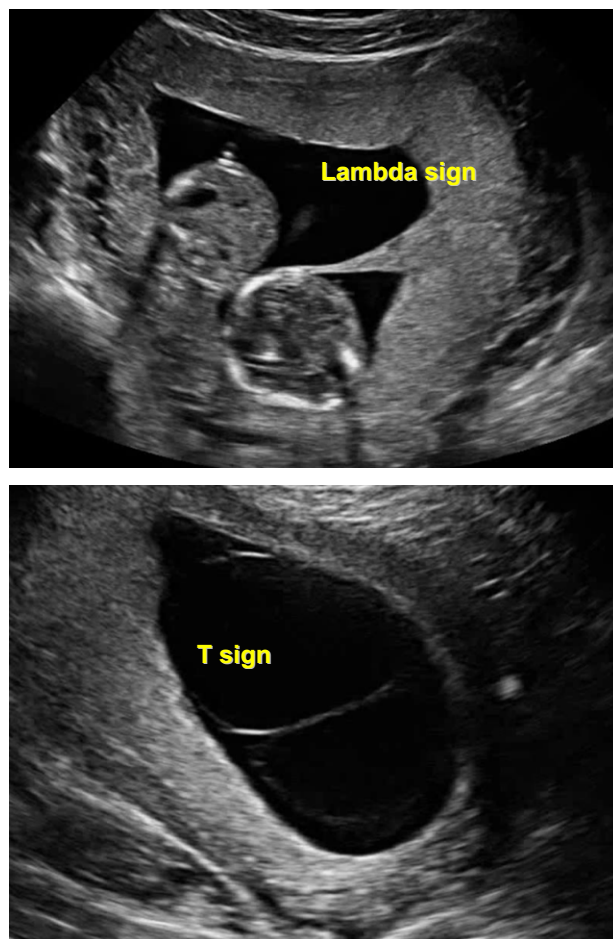
Clinical guidelines are: 'systematically developed statements which assist clinicians and patients in making decisions about appropriate treatment for specific conditions'. Each guideline is systematically developed using a standardised methodology. Exact details of this process can be found in Clinical Governance Advice No. 1 *Development of RCOG Green-top Guidelines* (available on the RCOG website at <http://www.rcog.org.uk/green-top-development>). These recommendations are not intended to dictate an exclusive course of management or treatment. They must be evaluated with reference to individual patient needs, resources and limitations unique to the institution and variations in local populations. It is hoped that this process of local ownership will help to incorporate these guidelines into routine practice. Attention is drawn to areas of clinical uncertainty where further research may be indicated.

The evidence used in this guideline was graded using the scheme below and the recommendations formulated in a similar fashion with a standardised grading scheme.

Classification of evidence levels	Grades of recommendations
<p>I++ High-quality meta-analyses, systematic reviews of randomised controlled trials or randomised controlled trials with a very low risk of bias</p> <p>I+ Well-conducted meta-analyses, systematic reviews of randomised controlled trials or randomised controlled trials with a low risk of bias</p> <p>I– Meta-analyses, systematic reviews of randomised controlled trials or randomised controlled trials with a high risk of bias</p> <p>2++ High-quality systematic reviews of case–control or cohort studies or high-quality case–control or cohort studies with a very low risk of confounding, bias or chance and a high probability that the relationship is causal</p> <p>2+ Well-conducted case–control or cohort studies with a low risk of confounding, bias or chance and a moderate probability that the relationship is causal</p> <p>2– Case–control or cohort studies with a high risk of confounding, bias or chance and a significant risk that the relationship is not causal</p> <p>3 Non-analytical studies, e.g. case reports, case series</p> <p>4 Expert opinion</p>	<p><b>A</b> At least one meta-analysis, systematic reviews or RCT rated as I++, and directly applicable to the target population; or A systematic review of RCTs or a body of evidence consisting principally of studies rated as I+, directly applicable to the target population and demonstrating overall consistency of results</p> <p><b>B</b> A body of evidence including studies rated as 2++ directly applicable to the target population, and demonstrating overall consistency of results; or Extrapolated evidence from studies rated as I++ or I+</p> <p><b>C</b> A body of evidence including studies rated as 2+ directly applicable to the target population, and demonstrating overall consistency of results; or Extrapolated evidence from studies rated as 2++</p> <p><b>D</b> Evidence level 3 or 4; or Extrapolated evidence from studies rated as 2+</p> <p><b>Good practice point</b></p> <p> Recommended best practice based on the clinical experience of the guideline development group</p>



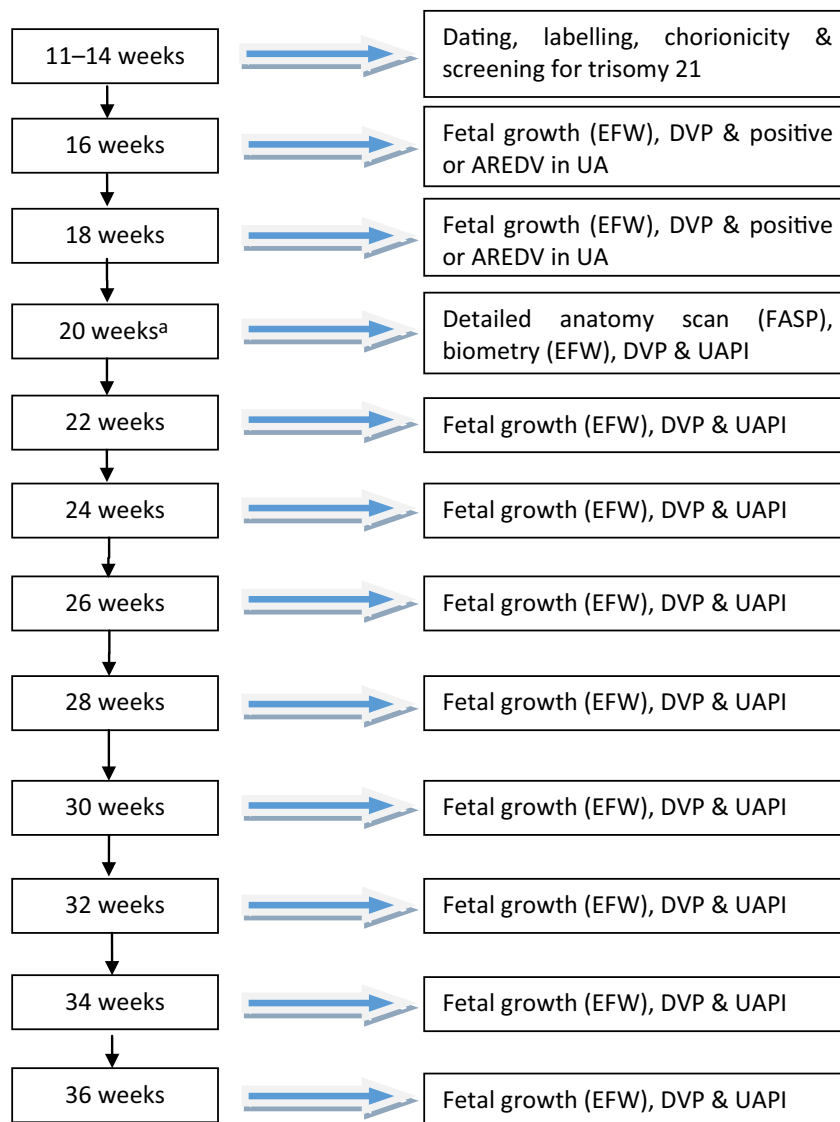
**Appendix II:** Ultrasound appearance of the membrane attachment to the placenta



**Reference:** Khalil A, Rodgers M, Baschat A, Bhide A, Gratacos E, Hecher K, et al. ISUOG Practice Guidelines: role of ultrasound in twin pregnancy. *Ultrasound Obstet Gynecol* 2016;47:247–63.

Copyright © 2015 ISUOG. Published by John Wiley & Sons Ltd.

### Appendix III: Assessment in uncomplicated monochorionic twin pregnancy

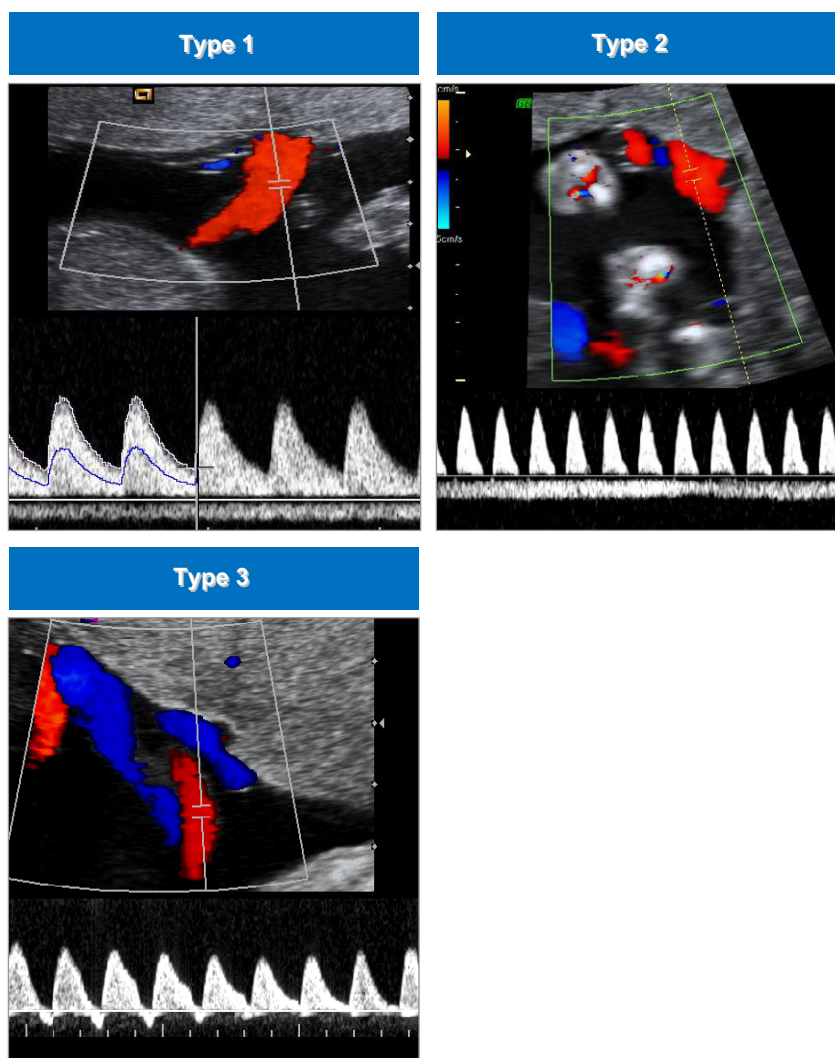


All routine antenatal assessment as in the NICE guidelines<sup>1</sup> should be followed.

<sup>a</sup>At the 20–24-week scan, routine cervical length measurement is not advocated<sup>1</sup> outside a randomised controlled trial.

**Abbreviations:** **AREDV** absent or reversed end-diastolic velocities; **DVP** deepest vertical pocket; **EFW** estimated fetal weight; **FASP** Fetal Anomaly Screening Programme; **UA** umbilical artery; **UAPI** umbilical artery pulsatility index.

## Appendix IV: Types of selective growth restriction



**Reference:** Khalil A, Rodgers M, Baschat A, Bhide A, Gratacos E, Hecher K, et al. ISUOG Practice Guidelines: role of ultrasound in twin pregnancy. *Ultrasound Obstet Gynecol* 2016;47:247–63.

Copyright © 2015 ISUOG. Published by John Wiley & Sons Ltd.

## Appendix V: Glossary of terms

Monochorionic; MC	Multiple pregnancy with single placenta.
Dichorionic; DC	Multiple pregnancy with two placentas.
Monoamniotic; MA	Single amniotic sac.
Diamniotic; DA	Two amniotic sacs.
Triamniotic; TA	Three amniotic sacs (in triplets).
Twin-to-twin transfusion syndrome; TTTS	A morbid condition affecting monochorionic twin pregnancies where there is significant discordance in inter-twin liquor volumes and cardiovascular measurements.
Twin anaemia-polycythaemia sequence; TAPS	An antenatal or postnatal diagnosis of significant haemoglobin difference between monochorionic twins (see text).
Middle cerebral artery peak systolic velocity; MCA PSV	The peak systolic velocity measured using Doppler insonation of the middle cerebral artery. The higher the MCA PSV, the lower the fetal haemoglobin.
Selective growth restriction; sGR	A difference of estimated fetal weight of more than 20% between twins.
Twin reversed arterial perfusion sequence; TRAP sequence	This is a monochorionic twin pregnancy where one twin, the 'pump' twin, is perfusing its co-twin, which has no cardiac activity and often is associated with major and lethal fetal anomalies.

This guideline was produced on behalf of the Royal College of Obstetricians and Gynaecologists by:

**Professor MD Kilby FRCOG, Birmingham; and Dr L Bricker FRCOG, Abu Dhabi, United Arab Emirates**

and peer reviewed by:

Dr F Audibert, Centre Hospitalier Universitaire Sainte-Justine, Université de Montréal, Montreal, Canada; Dr JFR Barrett FRCOG, Toronto, Canada; Professor FM Breathnach FRCOG, Dublin; Dr ACG Breeze MRCOG, Leeds; British Maternal and Fetal Medicine Society; Mrs AHD Diyaf MRCOG, Barnstaple; Professor Y Ezra, Hadassah Hebrew University Medical Centre, Jerusalem, Israel; Dr JL Gibson MRCOG, Glasgow; Dr JG Hall, Professor Emerita of Pediatrics and Medical Genetics, University of British Columbia and Children's & Women's Health Centre of British Columbia, Vancouver, Canada; Mr DT Howe FRCOG, Southampton; Mr B Kumar FRCOG, Wrexham; Dr L Lewi, University Hospitals Leuven, Belgium; Dr WL Martin FRCOG, Birmingham; Mrs G Masson FRCOG, Stoke-on-Trent, RCOG Ultrasound Officer; Dr SS Ong MRCOG, Belfast; RCOG Women's Network; Dr D Roberts MRCOG, Liverpool; Mr RPP Smith MRCOG, Norwich; Society and College of Radiographers; Dr SN Sturgiss MRCOG, Newcastle upon Tyne; The Multiple Births Foundation; Professor MJC van Gemert, Academic Medical Center, University of Amsterdam, Amsterdam, the Netherlands.

Committee lead reviewers were: Dr PS Arunakumari FRCOG, Basildon; Dr P Owen<sup>1</sup> FRCOG, Glasgow; and Mr RC Wimalasundera FRCOG, London.

The chairs of the Guidelines Committee were: Dr M Gupta<sup>2</sup> MRCOG, London; Dr P Owen<sup>1</sup> FRCOG, Glasgow, Scotland; and Dr AJ Thomson<sup>2</sup> MRCOG, Paisley.

<sup>1</sup>until May 2014 <sup>2</sup>co-chairs from June 2014.

*All RCOG guidance developers are asked to declare any conflicts of interest. A statement summarising any conflicts of interest for this guideline is available from: <https://www.rcog.org.uk/en/guidelines-research-services/guidelines/gtg51/>.*

The final version is the responsibility of the Guidelines Committee of the RCOG.

The review process will commence in 2019, unless otherwise indicated.

#### DISCLAIMER

The Royal College of Obstetricians and Gynaecologists produces guidelines as an educational aid to good clinical practice. They present recognised methods and techniques of clinical practice, based on published evidence, for consideration by obstetricians and gynaecologists and other relevant health professionals. The ultimate judgement regarding a particular clinical procedure or treatment plan must be made by the doctor or other attendant in the light of clinical data presented by the patient and the diagnostic and treatment options available.

This means that RCOG Guidelines are unlike protocols or guidelines issued by employers, as they are not intended to be prescriptive directions defining a single course of management. Departure from the local prescriptive protocols or guidelines should be fully documented in the patient's case notes at the time the relevant decision is taken.